

---

**Neurology Publish Ahead of Print**  
**DOI:10.1212/WNL.000000000207448**

Teaching NeuroImage: Cutaneous Lesions and Leptomeningeal Carcinomatosis in Gastric Signet-Ring Cell Carcinoma

**Author(s):**

Andrew Silverman, MD, MHS<sup>1</sup>; Deanne Loube, MD<sup>1</sup>; Martavius Lovall, MD<sup>1</sup>; Chrysa Cheronis, MD<sup>1</sup>; Evan Madill, MD<sup>1</sup>; Cristoph Karch, MD, PhD<sup>1,2</sup>

**Corresponding Author:**

Andrew Silverman, [andrew.silverman@stanford.edu](mailto:andrew.silverman@stanford.edu)

**Affiliation Information for All Authors:** 1. Department of Neurology, Stanford University School of Medicine, Palo Alto CA; 2. Department of Neurology, Santa Clara Valley Medical Center, San Jose CA.

**Equal Author Contribution:**

**Contributions:**

Andrew Silverman: Drafting/revision of the manuscript for content, including medical writing for content; Major role in the acquisition of data; Study concept or design; Analysis or interpretation of data

Deanne Loube: Drafting/revision of the manuscript for content, including medical writing for content; Major role in the acquisition of data

Martavius Lovall: Drafting/revision of the manuscript for content, including medical writing for content; Major role in the

acquisition of data

Chrysa Cheronis: Drafting/revision of the manuscript for content, including medical writing for content

Evan Madill: Drafting/revision of the manuscript for content, including medical writing for content; Major role in the acquisition of data

Cristoph Karch: Drafting/revision of the manuscript for content, including medical writing for content; Major role in the acquisition of data; Study concept or design; Analysis or interpretation of data

**Figure Count:**

1

**Table Count:**

0

**Search Terms:**

[ 15 ] Clinical neurology history, [ 16 ] Clinical neurology examination, [ 120 ] MRI, [ 217 ] Metastatic tumor

**Acknowledgment:**

**Study Funding:**

The authors report no targeted funding.

**Disclosure:**

The authors report no disclosures relevant to the manuscript.

**Preprint DOI:**

**Received Date:**

2022-11-14

**Accepted Date:**

2023-04-10

**Handling Editor Statement:**

Submitted and externally peer reviewed. The handling editor was Resident and Fellow Section Editor Whitley Aamodt, MD, MPH.

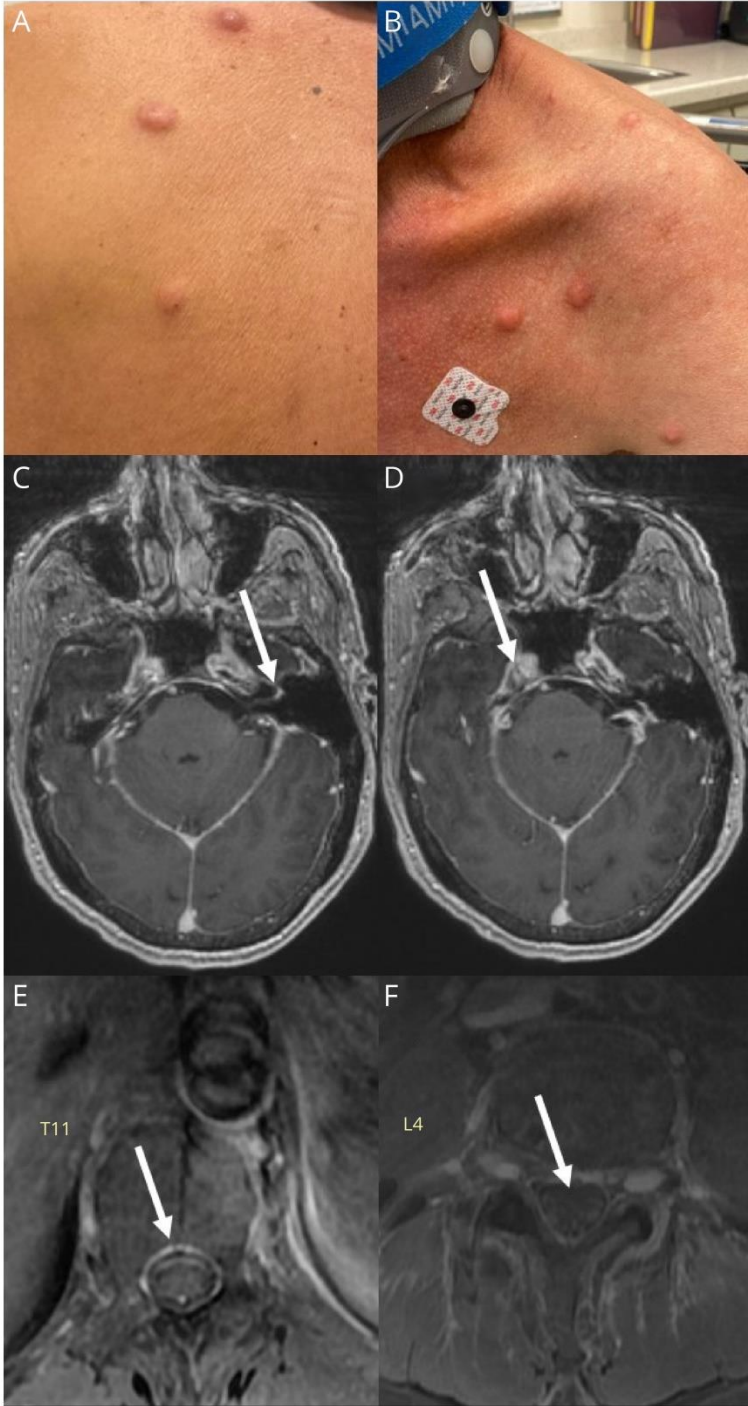
A 61-year-old male with a 47 pack-year smoking history presented after a month of positional headache, blurry vision, early satiety, and weight loss. His neurological exam demonstrated bilateral papilledema but was otherwise unremarkable. Lumbar puncture was significant for 40 cmH<sub>2</sub>O opening pressure, glucose 27 mg/dL, protein 48 mg/dL, 5 red blood cells, 8 leukocytes, and atypical keratin-positive cells. Skin exam revealed multiple nodules that had appeared a week prior to symptom onset (Figure, A and B). MRI showed enhancement of (Figure, C) the facial and vestibulocochlear nerve complex, (Figure, D) trigeminal nerve, (Figure, E) patchy spinal leptomeninges, and (Figure, F) cauda equina nerve roots. Skin lesion biopsy and CSF cytology both revealed signet-ring carcinoma. Subsequent endoscopy revealed primary gastric cell adenocarcinoma. Leptomeningeal carcinomatosis is rare and occurs in only 0.14-0.24% of all gastric carcinomas. [1,2] To our knowledge, cutaneous and concurrent leptomeningeal spread of gastric cancer has not been reported. This case highlights the relevance of a general exam and consideration of comorbidities in approaching an unclear neurological presentation, particularly when considering possible leptomeningeal disease.

WNL-2023-000281\_slides ---<http://links.lww.com/WNL/C861>

## References:

- 1) Guo JW, Zhang XT, Chen XS, Zhang XC, Zheng GJ, Zhang BP, Cai YF. Leptomeningeal carcinomatosis as the initial manifestation of gastric adenocarcinoma: a case report. *World J Gastroenterol.* 2014 Feb 28;20(8):2120-6.
- 2) Ali S, Khan MT, Idrisov EA, Maqsood A, Asad-Ur-Rahman F, Abusaada K. Signet Cell in the Brain: A Case Report of Leptomeningeal Carcinomatosis as the Presenting Feature of Gastric Signet Cell Cancer. *Cureus.* 2017 Mar 7;9(3):e1085.

**Figure: Examination and imaging findings.** Pink and violaceous papules and nodules on the (A) back, (B) shoulder and chest. Axial T1 post-contrast MRI brain sequences showing: (C) Linear enhancement of the left facial and vestibulocochlear nerve complex; (D) Enhancement of the right trigeminal nerve in Meckel's cave; (E) Leptomeningeal enhancement at the level of T11; (F) Cauda equina nerve root enhancement, cumulatively concerning for diffuse, patchy leptomeningeal disease.



REPEATED

# Neurology<sup>®</sup>

## Teaching NeuroImage: Cutaneous Lesions and Leptomeningeal Carcinomatosis in Gastric Signet-Ring Cell Carcinoma

Andrew Silverman, Deanne Loube, Martavius Lovall, et al.  
*Neurology* published online June 8, 2023  
DOI 10.1212/WNL.0000000000207448

**This information is current as of June 8, 2023**

|   |   |
|---|---|
| <b>Updated Information &amp; Services</b> | including high resolution figures, can be found at:<br><a href="http://n.neurology.org/content/early/2023/06/08/WNL.0000000000207448.citation.full">http://n.neurology.org/content/early/2023/06/08/WNL.0000000000207448.citation.full</a>  |
| <b>Subspecialty Collections</b>           | This article, along with others on similar topics, appears in the following collection(s):<br><b>Clinical neurology examination</b><br><a href="http://n.neurology.org/cgi/collection/clinical_neurology_examination">http://n.neurology.org/cgi/collection/clinical_neurology_examination</a><br><b>Clinical neurology history</b><br><a href="http://n.neurology.org/cgi/collection/clinical_neurology_history">http://n.neurology.org/cgi/collection/clinical_neurology_history</a><br><b>Metastatic tumor</b><br><a href="http://n.neurology.org/cgi/collection/metastatic_tumor">http://n.neurology.org/cgi/collection/metastatic_tumor</a><br><b>MRI</b><br><a href="http://n.neurology.org/cgi/collection/mri">http://n.neurology.org/cgi/collection/mri</a> |
| <b>Permissions &amp; Licensing</b>        | Information about reproducing this article in parts (figures, tables) or in its entirety can be found online at:<br><a href="http://www.neurology.org/about/about_the_journal#permissions">http://www.neurology.org/about/about_the_journal#permissions</a>   |
| <b>Reprints</b>                           | Information about ordering reprints can be found online:<br><a href="http://n.neurology.org/subscribers/advertise">http://n.neurology.org/subscribers/advertise</a>   |

*Neurology*® is the official journal of the American Academy of Neurology. Published continuously since 1951, it is now a weekly with 48 issues per year. Copyright © 2023 American Academy of Neurology. All rights reserved. Print ISSN: 0028-3878. Online ISSN: 1526-632X.

