
Neurology Publish Ahead of Print

DOI: 10.1212/WNL.000000000207447

Clinical Reasoning: A 62-Year-Old Woman With Transient Vision Loss

Author(s):

Leticia Maria Tedesco Silva, MD^{1,2}; Jenny Carolina Reategui, MD^{1,2}; Leticia Tornes, MD^{1,2,3}; Erika Marulanda, MD^{1,2}; Kamil Detyniecki, MD^{1,2}; Ayham Alkhachroum, MD^{1,2}; Jason Margolesky, MD^{1,2}; Manuel Melo Bicchi, MD^{1,2}

Corresponding Author:

Leticia Maria Tedesco Silva, tedesco.leticia@miami.edu

Affiliation Information for All Authors: 1. Department of Neurology, Miller School of Medicine, University of Miami, Miami, Florida, U.S.A.; 2. Neurology Services, University of Miami Hospital and Clinics and Jackson Memorial Hospital, Miami, Florida, U.S.A.; 3. Department of Neurology, Bruce W Carter VA Medical Center, Miami, FL, U.S.A.

Equal Author Contribution:

Contributions:

Leticia Maria Tedesco Silva: Drafting/revision of the manuscript for content, including medical writing for content; Major role in the acquisition of data; Study concept or design; Analysis or interpretation of data

Jenny Carolina Reategui: Drafting/revision of the manuscript for content, including medical writing for content; Major role in the acquisition of data; Study concept or design; Analysis or interpretation of data

Leticia Tornes: Drafting/revision of the manuscript for content, including medical writing for content; Study concept or design; Analysis or interpretation of data

Erika Marulanda: Drafting/revision of the manuscript for content, including medical writing for content

Kamil Detyniecki: Drafting/revision of the manuscript for content, including medical writing for content

Ayham Alkhachroum: Drafting/revision of the manuscript for content, including medical writing for content

Jason Margolesky: Drafting/revision of the manuscript for content, including medical writing for content; Major role in the acquisition of data; Study concept or design; Analysis or interpretation of data

Manuel Melo Bicchi: Drafting/revision of the manuscript for content, including medical writing for content; Major role in the acquisition of data; Study concept or design; Analysis or interpretation of data

Figure Count:

2

Table Count:

0

Search Terms:

[43] Optic neuritis; see Neuro-ophthalmology/Optic Nerve (S), [132] Autoimmune diseases, [134] Vasculitis, [188] Optic nerve, [195] Visual loss

Acknowledgment:**Study Funding:**

The authors report no targeted funding.

Disclosure:

L.M. Tedesco Silva reports no disclosures relevant to the manuscript; J.C. Reategui reports no disclosures relevant to the manuscript; L. Tornes reports no disclosures relevant to the manuscript; E. Marulanda reports no disclosures relevant to the manuscript; K. Detyniecki reports no disclosures relevant to the manuscript; A. Alkhachroum is supported by an institutional KL2 Career Development Award from the Miami CTSI NCATS UL1TR002736, and by the National Institute of Neurological Disorders and Stroke of the National Institutes of Health under Award Number K23NS126577 & R21NS128326; J. Margolesky reports no disclosures relevant to the manuscript; M. Melo Bicchi reports no disclosures relevant to the manuscript.

Preprint DOI:**Received Date:**

2022-11-10

Accepted Date:

2023-04-10

Handling Editor Statement:

Submitted and externally peer reviewed. The handling editor was Resident and Fellow Deputy Editor Katherine Fu, MD.

Abstract:

Transient visual loss (TVL) is a common complaint in the Emergency Department, with numerous possible etiologies. Prompt evaluation and management of TVL can potentially prevent progression to permanent visual loss. In this case, a 62-year-old female presented with acute, painless, unilateral TVL. Two weeks prior to presentation, the patient reported bitemporal headaches and paresthesia of the distal extremities. A review of systems revealed chronic fatigue, cough, diffuse arthralgias, and decreased appetite for the previous six months. This case highlights the diagnostic approach to patients with TVL. Some common and rare causes associated with this clinical manifestation are briefly reviewed.

Section 1

A 62-year-old female with a medical history of asthma presented to the emergency department with painless transient vision loss (TVL) of the left eye lasting 15 minutes with complete resolution. Similar symptoms were reported in the contralateral eye six days before presentation. In the past two weeks, she complained of persistent dull bitemporal headaches associated with photophobia and worsening numbness of bilateral hands and feet. A review of systems revealed fatigue, cough, arthralgias, and decreased appetite for the past six months. She denied any focal weakness, weight loss, preceding infectious illness, or trauma. Her medication regimen included inhaled ipratropium, intranasal fluticasone, and oral montelukast.

Neurologic examination showed an awake and oriented woman with prosodic and fluent speech. Pupils were symmetric and reactive to bright light. No afferent pupillary defect, ophthalmoplegia, or nystagmus were detected, visual fields were full to confrontation, visual acuity was 20/20, intraocular pressure was 23, and extraocular movements were full without pain or diplopia on the far gaze, bilaterally. On dilated fundoscopic examination, both eyes vitreous, macula, vessels, and periphery were within normal limits. The disk had sharp margins and normal color, without edema, and a cup-to-disc ratio of 0.8 with a cupped appearance. Pinprick, vibration, and proprioception were mildly decreased at the toes and hands bilaterally. Manual motor testing revealed grade 5/5 strength in proximal and distal upper and lower extremities. Finger-to-nose and heel-to-shin revealed no ataxia or dysmetria. Reflexes were preserved.

Skin examination revealed erythematous maculopapular lesions with central purple involving the right dorsal foot and ankle. There were scattered erythematous papules on the bilateral lower extremities and right arm.

Questions for consideration

1. What is the differential diagnosis?
2. What diagnostic work-up should be done?

Go to Section 2

Section 2

The patient in this vignette presented with painless unilateral TVL and bitemporal headache. Causes of TVL can be divided into ischemic or non-ischemic. The most common cause of TVL is ischemic optic neuropathy (arteritic or nonarteritic). Therefore, patients presenting with these symptoms require urgent evaluation since delay can quickly lead to infarction. Risk factors for nonarteritic optic nerve ischemia include older age, hypertension, and diabetes. Carotid imaging duplex ultrasound, magnetic resonance angiography, or computed tomographic angiography) is required, especially if vascular risk factors are present.¹ Computed tomography angiography of the head and neck showed no evidence of large vessel arteritis, normal superficial temporal artery bilaterally, and no atherosclerotic disease.

Optic nerve ischemia can be attributed to embolism, coagulopathy, vasospasm, or vasculitis. A detailed funduscopic examination could reveal the implicated mechanism and is part of the diagnostic workup for TVL. In patients older than 50 years of age, it is recommended to obtain erythrocyte sedimentation rate (ESR) and C-reactive protein to screen for Giant Cell Arteritis (GCA), the most common cause of arteritic ischemic optic neuropathy, and a treatable cause of otherwise permanent visual loss. Risk factors for arteritic ischemic optic neuropathy include female sex and older age.² Headache is more common in GCA than in carotid vascular disease and could help differentiate these two conditions; temporal artery biopsy can be diagnostic.³

Non-ischemic etiologies for optic neuropathies include infectious (West Nile virus, Syphilis), inflammatory (post viral optic neuritis, sarcoidosis, autoimmune disease), toxins (methanol, ethambutol), or nutritional deficiency (vitamin B1, B12). Brain lesions can also cause compression of the optic nerve, typically identified in neuroimaging and usually presenting as chronic, progressive vision loss.⁴ Transient visual loss and headache, particularly positional headaches, could be a manifestation of idiopathic intracranial hypertension. Common MRI findings include optic nerve tortuosity and bulging, empty sella turcica, posterior globe flattening, and transverse sinus stenosis. Lumbar puncture with opening pressure can be both diagnostic and therapeutic, although not pathognomonic.⁵

Demyelinating etiologies for optic neuropathy causing optic neuritis are Multiple Sclerosis (MS), Myelin Oligodendrocyte glycoprotein antibody-associated disease (MOGAD), or Neuromyelitis Optic Spectrum Disorder (NMOSD). The vision loss in these disorders is painful and not transient, lasting days to weeks. MRI findings and associated antibody testing are diagnostic for these conditions.⁶

Initial workup included an MRI brain (Figure 1), cerebral spinal fluid (CSF), autoimmune panel, inflammatory markers, urinalysis, and vitamins B12 and B9 levels. The MRI revealed retrobulbar, and perioptic nerve sheath enhancement associated with mild leptomeningeal enhancement and extensive sinus disease. She underwent lumbar puncture with normal opening pressure, CSF analysis showed increased IgG (3.6) and white blood cell count 9/mm³, with increased eosinophils (11% neutrophils, 33% lymphocytes, 22% monocytes, 33%

eosinophils), normal protein (42 mg/dL), and glucose (56 mg/dL). Immunological workup was positive for antinuclear antibodies (1:160) and myeloperoxidase anti-neutrophil cytoplasmic antibody (MPO-ANCA). ANCA-PR3 was negative. Her ESR (46 mm/hr.) was mildly elevated. Peripheral cell blood count demonstrated significant eosinophilia (6440/mm³). Urinalysis showed microhematuria (6 RBC/HPF). Vitamin B12 and B9 were within normal limits.

Questions for consideration

1. What additional test can narrow the differential diagnosis?
2. How would you treat the patient?

Go to Section 3

Section 3

The inflammation was confined to the optic nerve sheath, conferring optic perineuritis as opposed to optic neuritis that presents with inflammation of the optic nerve axons. Some etiologies for optic perineuritis include Grave's disease, sarcoidosis, rheumatoid arthritis, scleroderma, gout, tuberculosis, sparganosis, ocular toxoplasmosis, bacterial and fungal meningitis, IgG4 related diseases, CMV neuroretinitis, Behcet's disease, and granulomatosis with polyangiitis. Most cases of optic perineuritis are associated with systemic autoimmune diseases, in contrast to optic neuritis that is more commonly associated with central nervous system (CNS) autoimmune disorders such as MS, MOGAS or NMOSD.⁷

Optic perineuritis and systemic symptoms with sinuses/lung involvement suggests an autoimmune/inflammatory or infectious etiology. Work-up included negative blood testing for syphilis, HIV, hepatitis, tuberculosis, strongyloidiasis, parasites, meningoencephalitis panel, and negative CSF gram stain/cultures. Serum levels of angiotensin converting enzyme, copper, methylmalonic acid, and vitamin B6 were normal. Nerve conduction studies revealed peripheral sensorimotor axonal neuropathy affecting lower extremities more than upper extremities-

Considering the patient's eosinophilia, neurologic symptoms (TVL and peripheral neuropathy), sinus abnormalities, optic perineuritis, history of asthma, cutaneous palpable purpura, arthralgias, and MPO-ANCA positivity; a diagnosis of Eosinophilic Granulomatosis with

Polyangiitis (EGPA) was made. Intravenous methylprednisolone was started and continued for three days followed by a daily oral maintenance dose of prednisone. On the second day of treatment, the patient denied new episodes of visual loss, headaches, paresthesias, or other neurological symptoms. Her eosinophil count reduced to $44/\text{mm}^3$ after treatment. The rheumatology team recommended a course of cyclophosphamide. Montelukast was discontinued as there were reported cases of an association with EGPA.⁸

The purpuric rash on the ankle (Figure 2A) was biopsied, showing eosinophilic and neutrophilic infiltration and vasculitis (Figure 2B, 2C, and 2D). Biopsy results were compatible with bullous eosinophilic vasculitis. The patient was discharged with oral prednisone 35 mg daily, that was tapered off as outpatient. After clinical remission, methotrexate was started as maintenance therapy. The patient continues to be in clinical remission to the publication of this case, approximately seventeen months after her admission.

Discussion:

This case illustrates TVL as a possible, but unusual, CNS manifestation of EGPA. EGPA is a rare necrotizing vasculitis of small and medium-sized vessels that involves multiple organs. Clinical clues included (1) the systemic and constitutional symptoms in combination with upper and lower airway dysfunction and (2) palpable purpura, a common dermatologic finding in many small-vessel vasculitis.

The American College of Rheumatology established a classification criterion for EGPA, after a diagnosis of small or medium vessel vasculitis has been made: maximum eosinophil count $\geq 1 \times 10^9/\text{L}$ (+5), obstructive airway disease (+3), nasal polyps (+3), cytoplasmic antineutrophil cytoplasmic antibody (c-ANCA) or anti-proteinase 3-ANCA positivity (-3), extravascular eosinophilic predominant inflammation (+2), mononeuritis multiplex/motor neuropathy not due to radiculopathy (+1) and hematuria (-1). A total risk score ≥ 6 , as seen in this case, yielded a sensitivity of 84.9% and a specificity of 99.1% for EGPA.⁹

In a 46-cases review of the ophthalmic manifestations of EGPA¹⁰, central retinal artery or vein occlusion, ischemic optic neuropathy, conjunctival nodules, orbital myositis, proptosis, dacryoadenitis, retinal vasculitis/infarcts/edema, cranial nerve palsy, and amaurosis were reported. On imaging, the most common findings include orbital mass or infiltration; enhancement or enlargement of rectus muscles; lacrimal gland involvement; and enhancement along the optic nerve sheath. The ophthalmic presentations were divided in two groups: idiopathic orbital inflammation-like or ischemic vasculitis. The most common presenting

symptoms in the idiopathic orbital inflammation-like group were redness, periocular swelling, and diplopia. In contrast, patients in the ischemic vasculitis group presented most frequently with acute-onset loss of vision. At least 6 patients with the ischemic vasculitis type reported episodes of unilateral TVL prior to permanent visual loss. Of the 8 patients with ischemic vasculitis, three had improvement in visual outcomes following intravenous steroids therapy, reinforcing the importance of correct identification and treatment of the ophthalmic manifestations of EGPA.

In this case, the patient presented with a chief complaint of TVL and clinical findings compatible with EGPA. Although rare, TVL is among the ophthalmic manifestations of EGPA. Knowledge of the ophthalmic manifestations of EGPA may yield prompt diagnosis and treatment, decreasing patient morbidity and mortality.^{7,11,10}

Figure 1.Brain MRI

A and B) Axial FLAIR brain MRI demonstrates hyperintensity of the periorbital soft tissue, temporalis muscle, and extensive ethmoid and maxillary sinus disease (green arrows). C) Coronal T1 without contrast. D) Coronal T1 sequence with contrast showing optic perineuritis and fat stranding (yellow arrow). Note the enlarged inferior turbinate (red arrow). E) Axial T1 without contrast. F) Axial T1 with contrast showing perioptic nerve enhancement (yellow arrows).

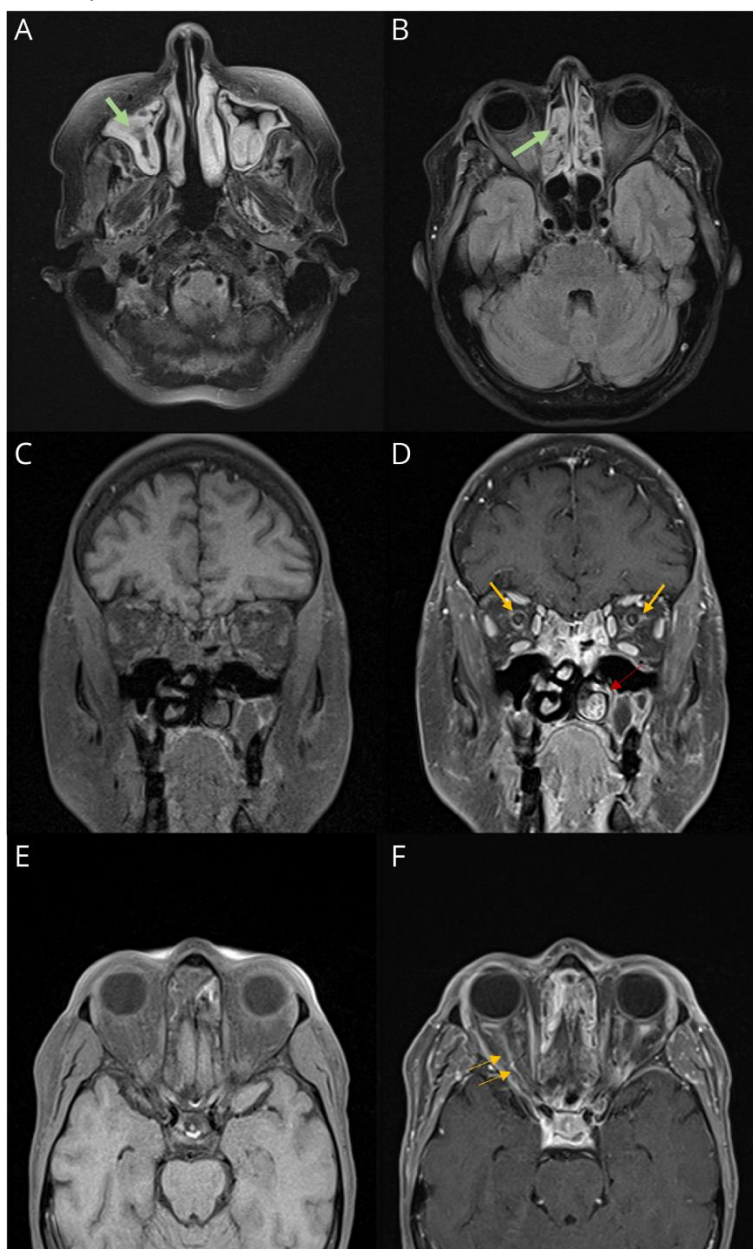
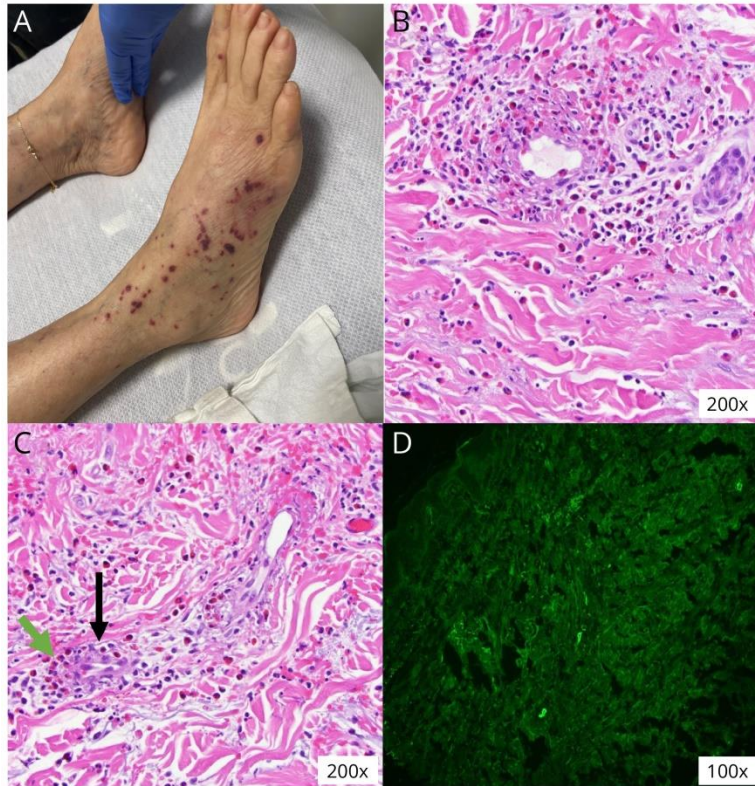


Figure 2. Histopathological features

A) Palpable non-blanching lesions suggestive of cutaneous vasculitis. B and C) Skin biopsy showing eosinophilic infiltration (green arrow) around vessels (black arrow). D) On direct immunofluorescence, skin vessels stained positive for antibodies against IgG, IgM, C3 and fibrinogen; intercellular basement membrane and superficial dermis stained negative for antibodies.



References

1. Volkens EJ, Donders RC, Koudstaal PJ, van Gijn J, Algra A, Jaap Kappelle L. Transient monocular blindness and the risk of vascular complications according to subtype: a prospective cohort study. *J Neurol*. 2016;263(9):1771-7; doi:10.1007/s00415-016-8189-x
2. Machado EB, Michet CJ, Ballard DJ, et al. Trends in incidence and clinical presentation of temporal arteritis in Olmsted County, Minnesota, 1950-1985. *Arthritis Rheum*. 1988;31(6):745-9; doi:10.1002/art.1780310607
3. Vodopivec I, Rizzo JF, 3rd. Ophthalmic manifestations of giant cell arteritis. *Rheumatology (Oxford)*. 2018;57(suppl_2):ii63-ii72; doi:10.1093/rheumatology/kex428
4. Van Stavern GP. Metabolic, hereditary, traumatic, and neoplastic optic neuropathies. *Continuum (Minneap Minn)*. 2014;20(4 Neuro-ophthalmology):877-906; doi:10.1212/01.CON.0000453313.37143.9b
5. Friedman DI, Liu GT, Digre KB. Revised diagnostic criteria for the pseudotumor cerebri syndrome in adults and children. *Neurology*. 2013;81(13):1159-65; doi:10.1212/WNL.0b013e3182a55f17
6. Sechi E, Cacciaguerra L, Chen JJ, et al. Myelin Oligodendrocyte Glycoprotein Antibody-Associated Disease (MOGAD): A Review of Clinical and MRI Features, Diagnosis, and Management. *Front Neurol*. 2022;13:885218; doi:10.3389/fneur.2022.885218
7. Li H, Zhou H, Sun J, et al. Optic Perineuritis and Its Association With Autoimmune Diseases. *Front Neurol*. 2021;11:627077; doi:10.3389/fneur.2020.627077
8. Giusti Del Giardino L, Cavallaro T, Anzola GP, Lombardi C, Ferrari S. Neuropathy in eosinophilic granulomatosis with polyangiitis: a comparison study of 24 cases with or without prior leukotriene antagonist exposure. *Eur Ann Allergy Clin Immunol*. 2014;46(6):201-9.
9. Grayson PC, Ponte C, Suppiah R, et al. 2022 American College of Rheumatology/European Alliance of Associations for Rheumatology Classification Criteria for Eosinophilic Granulomatosis with Polyangiitis. *Ann Rheum Dis*. 2022;81(3):309-314; doi:10.1136/annrheumdis-2021-221794
10. Akella SS, Schlachter DM, Black EH, Barmettler A. Ophthalmic Eosinophilic Granulomatosis With Polyangiitis (Churg-Strauss Syndrome): A Systematic Review of the Literature. *Ophthalmic Plast Reconstr Surg*. 2019;35(1):7-16; doi:10.1097/iop.0000000000001202
11. André R, Cottin V, Saraux JL, et al. Central nervous system involvement in eosinophilic granulomatosis with polyangiitis (Churg-Strauss): Report of 26 patients and review of the literature. *Autoimmun Rev*. 2017;16(9):963-969; doi:10.1016/j.autrev.2017.07.007

Neurology®

Clinical Reasoning: A 62-Year-Old Woman With Transient Vision Loss
Leticia Maria Tedesco Silva, Jenny Carolina Reategui, Leticia Tornes, et al.
Neurology published online June 8, 2023
DOI 10.1212/WNL.0000000000207447

This information is current as of June 8, 2023

Updated Information & Services	including high resolution figures, can be found at: http://n.neurology.org/content/early/2023/06/08/WNL.0000000000207447.full
Subspecialty Collections	This article, along with others on similar topics, appears in the following collection(s): Autoimmune diseases http://n.neurology.org/cgi/collection/autoimmune_diseases Optic nerve http://n.neurology.org/cgi/collection/optic_nerve Optic neuritis; see Neuro-ophthalmology/Optic Nerve http://n.neurology.org/cgi/collection/optic_neuritis Vasculitis http://n.neurology.org/cgi/collection/vasculitis Visual loss http://n.neurology.org/cgi/collection/visual_loss
Permissions & Licensing	Information about reproducing this article in parts (figures, tables) or in its entirety can be found online at: http://www.neurology.org/about/about_the_journal#permissions
Reprints	Information about ordering reprints can be found online: http://n.neurology.org/subscribers/advertise

Neurology® is the official journal of the American Academy of Neurology. Published continuously since 1951, it is now a weekly with 48 issues per year. Copyright © 2023 American Academy of Neurology. All rights reserved. Print ISSN: 0028-3878. Online ISSN: 1526-632X.

