

Teaching NeuroImage: Horizontal Diplopia Due to Extraocular Muscle Metastasis

Merve Atik, MD, David Nathan Abarbanel, MD, and Ugur Sener, MD

Neurology® 2022;99:669-670. doi:10.1212/WNL.000000000000201061

Correspondence

Dr. Sener

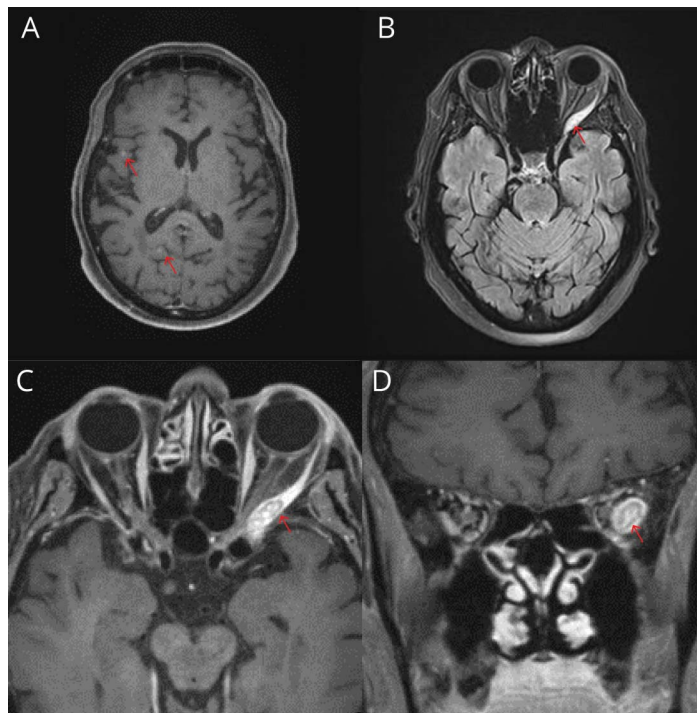
sener.ugur@mayo.edu

MORE ONLINE

Teaching slides

links.lww.com/WNL/C261

Figure MRI of the Brain and Orbits



(A) Postcontrast T1-weighted MRI axial demonstrating subcentimeter right frontal and right occipital enhancing lesions consistent with metastasis (arrows). (B) T2-weighted fluid-attenuated inversion recovery MRI demonstrating left lateral rectus lesion (arrow). (C) Postcontrast T1-weighted MRI of the orbits demonstrating enhancing lesion involving left lateral rectus (arrow) in axial view. (D) Postcontrast T1-weighted MRI of the orbits demonstrating enhancing lesion involving left lateral rectus (arrow) in coronal view.

An 80-year-old woman with previously resected melanoma of the right thigh presented with acute binocular diplopia. Neurologic examination demonstrated inability to abduct the left eye with normal right eye adduction. Examination was otherwise normal. This presentation of left lateral rectus palsy can occur due to ischemic, inflammatory, autoimmune, compressive, or neoplastic etiologies. MRI orbits identified an enhancing left lateral rectus lesion consistent with extraocular muscle metastasis. MRI of the brain revealed multiple subcentimeter-enhancing lesions (Figure).¹ Subsequent lymph node biopsy confirmed metastatic melanoma. Despite radiotherapy and BRAF-targeted systemic therapy, rapid progression occurred, and the patient died 5 months after initial evaluation.²

Study Funding

No targeted funding reported.

From the Department of Neurology, Mayo Clinic, Rochester, MN.

Go to Neurology.org/N for full disclosures. Funding information and disclosures deemed relevant by the authors, if any, are provided at the end of the article.

Copyright © 2022 American Academy of Neurology

Copyright © 2022 American Academy of Neurology. Unauthorized reproduction of this article is prohibited.

Disclosure

The authors report no relevant disclosures. Go to Neurology.org/N for full disclosures.

Publication History

Received by *Neurology* January 10, 2022. Accepted in final form June 17, 2022. Submitted and externally peer reviewed. The handling editor was Roy Strowd III, MD, MEd, MS.

Appendix Authors

Name	Location	Contribution
Merve Atik, MD	Department of Neurology, Mayo Clinic, Rochester, MN	Drafting/revision of the manuscript for content, including medical writing for content; major role in the acquisition of data; study concept or design; analysis or interpretation of data

Appendix (continued)

Name	Location	Contribution
David Nathan Abarbanel, MD	Department of Neurology, Mayo Clinic, Rochester, MN	Drafting/revision of the manuscript for content, including medical writing for content; major role in the acquisition of data; study concept or design; analysis or interpretation of data
Ugur Sener, MD	Department of Neurology, Mayo Clinic, Rochester, MN	Drafting/revision of the manuscript for content, including medical writing for content; major role in the acquisition of data; study concept or design; analysis or interpretation of data

References

1. Leung V, Wei M, Roberts TV. Metastasis to the extraocular muscles: a case report, literature review and pooled data analysis. *Clin Exp Ophthalmol*. 2018;46(6):687-694. doi:10.1111/ceo.13162.
2. Dummer R, Ascierto PA, Gogas HJ, et al. Encorafenib plus binimetinib versus vemurafenib or encorafenib in patients with BRAF-mutant melanoma (COLUMBUS): a multicentre, open-label, randomised phase 3 trial. *Lancet Oncol*. 2018;19(5):603-615. doi:10.1016/S1470-2045(18)30142-6.

Neurology® Online CME Program

Earn CME while reading *Neurology*. This program is available to AAN members and to online *Neurology* subscribers. Read the articles marked CME, go to Neurology.org, and click on the CME link. The American Academy of Neurology (AAN) is accredited by the Accreditation Council for Continuing Medical Education (ACCME) to sponsor continuing medical education for physicians. *Neurology* is planned and produced in accordance with the ACCME Essentials. For more information, contact AAN Member Services at 800-879-1960.

Disputes & Debates: Rapid Online Correspondence

The editors encourage comments on recent articles through Disputes & Debates:

Access an article at Neurology.org/N and click on “MAKE COMMENT” beneath the article header.

Before submitting a comment to Disputes & Debates, remember the following:

- Disputes & Debates is restricted to comments about articles published in *Neurology* within 6 months of issue date, but the editors will consider a longer time period for submission if they consider the letter a significant addition to the literature
- Read previously posted comments; redundant comments will not be posted
- Your submission must be 200 words or less and have a maximum of 5 references; the first reference must be the article on which you are commenting
- You can include a maximum of 5 authors (including yourself)

Neurology®

Teaching NeuroImage: Horizontal Diplopia Due to Extraocular Muscle Metastasis

Merve Atik, David Nathan Abarbanel and Ugur Sener

Neurology 2022;99:669-670 Published Online before print August 19, 2022

DOI 10.1212/WNL.0000000000201061

This information is current as of August 19, 2022

Updated Information & Services	including high resolution figures, can be found at: http://n.neurology.org/content/99/15/669.full
References	This article cites 2 articles, 0 of which you can access for free at: http://n.neurology.org/content/99/15/669.full#ref-list-1
Subspecialty Collections	This article, along with others on similar topics, appears in the following collection(s): All Oncology http://n.neurology.org/cgi/collection/all_oncology Diplopia (double vision) http://n.neurology.org/cgi/collection/diplopia_double_vision Metastatic tumor http://n.neurology.org/cgi/collection/metastatic_tumor MRI http://n.neurology.org/cgi/collection/mri Orbit http://n.neurology.org/cgi/collection/orbit
Permissions & Licensing	Information about reproducing this article in parts (figures, tables) or in its entirety can be found online at: http://www.neurology.org/about/about_the_journal#permissions
Reprints	Information about ordering reprints can be found online: http://n.neurology.org/subscribers/advertise

Neurology® is the official journal of the American Academy of Neurology. Published continuously since 1951, it is now a weekly with 48 issues per year. Copyright © 2022 American Academy of Neurology. All rights reserved. Print ISSN: 0028-3878. Online ISSN: 1526-632X.

