

Future of Neurology & Technology: Neuroimaging Made Accessible Using Low-Field, Portable MRI

Nethra R. Parasuram, BS, Anna L. Crawford, MS, Mercy H. Mazurek, BS, Isha R. Chawva, BS, Rachel Beekman, MD, Emily J. Gilmore, MD, Nils H. Petersen, MD, Seyedmehdi Payabvash, MD, Gordon Sze, MD, FACR, Juan Eugenio Iglesias, PhD, Sacit B. Omay, MD, FAANS, Charles Matouk, MD, Erin E. Longbrake, MD, PhD, Adam de Havenon, MD, Steven J. Schiff, MD, PhD, Matthew S. Rosen, PhD, W. Taylor Kimberly, MD, PhD, and Kevin N. Sheth, MD

Correspondence

Dr. Sheth
kevin.sheth@yale.edu

Neurology® 2023;100:1067-1071. doi:10.1212/WNL.0000000000207074

Abstract

In the 20th century, the advent of neuroimaging dramatically altered the field of neurologic care. However, despite iterative advances since the invention of CT and MRI, little progress has been made to bring MR neuroimaging to the point of care. Recently, the emergence of a low-field (<1 T) portable MRI (pMRI) is setting the stage to revolutionize the landscape of accessible neuroimaging. Users can transport the pMRI into a variety of locations, using a standard 110–220 V wall outlet. In this article, we discuss current applications for pMRI, including in the acute and critical care settings, the barriers to broad implementation, and future opportunities.

From the Department of Neurology (N.R.P., A.L.C., M.H.M., I.R.C., R.B., E.J.G., N.H.P., E.E.L., A.d.H., K.N.S.), and Department of Radiology (S.P., G.S.), Yale University School of Medicine, New Haven, CT; Computer Science and Artificial Intelligence Laboratory (CSAIL) (J.E.I.), Massachusetts Institute of Technology, Cambridge; Athinoula A. Martinos Center for Biomedical Imaging (J.E.I., M.S.R.), Massachusetts General Hospital, Charlestown; Department of Neurosurgery (S.B.O., C.M.), Yale University School of Medicine, New Haven, CT; Department of Neurosurgery (S.J.S.), Engineering Science and Mechanics, and Physics, The Pennsylvania State University, University Park; and Division of Neurocritical Care (W.T.K.), Department of Neurology, Massachusetts General Hospital, Boston.

Go to [Neurology.org/N](https://www.neurology.org/N) for full disclosures. Funding information and disclosures deemed relevant by the authors, if any, are provided at the end of the article.

In 1971, the development of CT transformed neuroimaging. For the first time, the brain could be visualized noninvasively.¹ MRI further revolutionized noninvasive diagnostic neuroimaging by leveraging magnetic resonance methods and magnetic gradient-based spatial encoding to provide greater soft tissue contrast and more precise anatomic visualization than CT.^{2,3} However, conventional MRI (cMRI) scanners operate at a high magnetic field strength (1.5–3 T), are costly to purchase (\$1 M per T), and require expensive infrastructure.⁴ Patients must be moved from clinical environments to controlled access remote imaging suites, often causing delays in image acquisition. This transport is associated with cardiovascular and respiratory risks, which are exacerbated by the inability to deploy interventions in transit.^{5,6} While the use of portable CT (pCT) can evade these hazards, it carries the risk of radiation.⁷ Thus, the ability to obtain MR neuroimaging at the point of care may reshape neurologic care (Figure).

For more information on portable MRI (pMRI) background, please refer to eAppendix 1 (links.lww.com/WNL/C622), which includes a discussion of pMRI vs cMRI and pCT and an explanation of pMRI specifications. eAppendix 1 also involves a clinical case highlighting pMRI's utility and a description of similar devices.

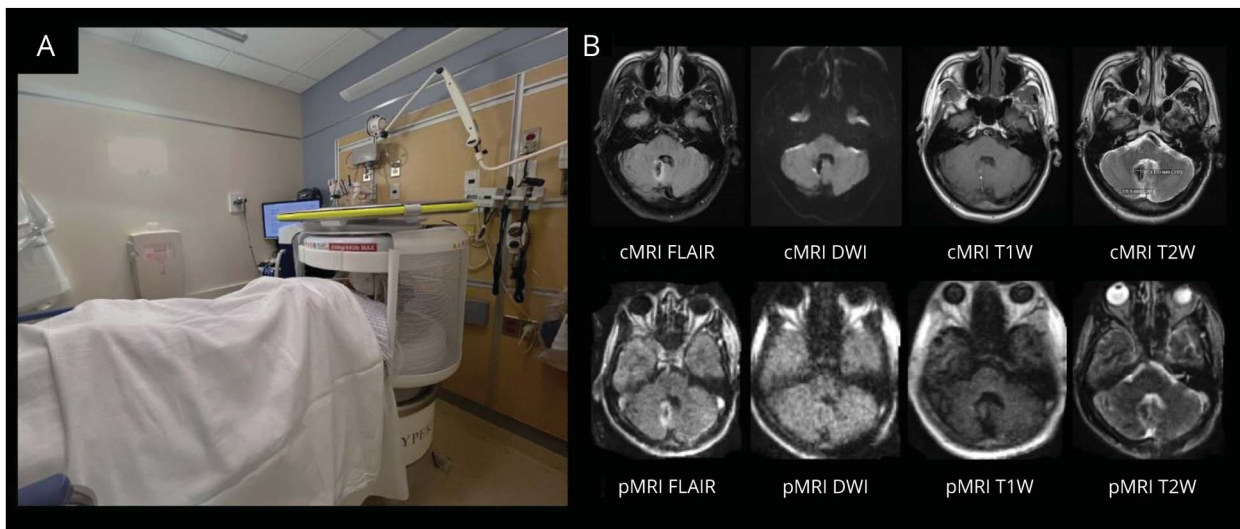
Present Deployments

Several reports have been published describing the safe deployment of pMRI in clinical settings, including in situations where coronavirus disease 2019 (COVID-19) restricted access to conventional neuroimaging due to the risk of spreading infection.^{8,9} This work demonstrates the advantages of pMRI,

which are exemplified by its ability to detect a previously unknown infarction in a COVID-positive patient, later confirmed by CT,⁹ and the opportunity to obtain serial neuroimaging of patients. Beyond the ICUs, pMRI is potentially effective in acute environments. Work conducted in the emergency department (ED) setting suggests its potential utility in supplementing hyperacute neurologic assessments for patients experiencing stroke symptoms.¹⁰ For example, when acute ischemic stroke (AIS) is suspected but CT has not revealed infarction, pMRI may potentially aid in the identification of acute infarction and guide subsequent intervention. pMRI also eliminates the need for patient transfer to CT scanner and onto scanner table because patients stay on their stretcher for the duration of the scan. This may assist with the busy environment of the ED. Furthermore, work in the operating room setting has illustrated the viability of pMRI for tracking post-surgical changes including confirming the correct placement of ventriculoperitoneal shunts.¹¹

In addition, recent studies have established the ability of pMRI to detect critical neuropathologies including intracerebral hemorrhage (ICH),¹² midline shift (MLS),¹³ AIS,¹⁴ subarachnoid hemorrhage, brain tumors, and traumatic brain injury.¹¹ Prior work has demonstrated sensitivity and specificity of 80.4% and 96.6% for ICH and 93% and 96% for MLS, respectively, when compared with standard-of-care imaging. Infarcts were detected in 90% of known cases of AIS evaluated in Yuen et al.¹⁴ Moreover, pMRI can be used as a prognostic tool because ICH volumes, ischemic infarct volumes, and MLS identified on pMRI have been shown to correlate with patient outcome.^{12–14} Outside of pathology evaluation, there is preliminary evidence for this technology's utility in the pediatric population, which may hold promise to better understand brain development.¹⁵

Figure (A) pMRI in an Emergency Department and (B) Representative Images From a pMRI Scan



(A) A patient scanned in low-field, pMRI in the emergency department with emergency department equipment operational during scanning. (B) Paired images for comparison of high-field cMRI and low-field pMRI in a patient with a right cerebellar hemorrhage with extension into the fourth ventricle. cMRI = conventional MRI; DWI = diffusion-weighted imaging; FLAIR = fluid-attenuated inversion recovery; pMRI = portable MRI; T1W = T1-weighted; T2W = T2-weighted.

Barriers to Use

While a low magnetic field strength increases neuroimaging access, it necessitates trade-offs in image resolution and acquisition time. Low-field (LF) MR image quality is lower than that of high field (HF) MRI due to decreased resolution as a consequence of lower signal-to-noise ratio (SNR). Leveraging currently evolving advanced machine learning (ML) tools may help compensate for this in the future. In addition to ML built into current software, other ML tools are being developed. Automated Transform by Manifold Approximation (AUTOMAP) is an image reconstruction tools that boosts SNR by treating reconstruction as a supervised learning task. As opposed to the standard Inverse Fast Fourier Transform method of transforming raw k-space data, AUTOMAP uses the forward encoding model to build images with less noise and clearer brain structures.^{e1}

Another set of methods of image reconstruction involves super resolution (SR) algorithms, which take advantage of deep convolutional neural networks trained with high-resolution images and low-resolution counterparts. One common challenge of these SR methods is the inability to accurately align HF with LF images. Another challenge is the inaccurate simulation of LF images using downsampled HF images. A newer tool, *SynthSR*, can be used to overcome these obstacles, producing higher-resolution images from which reliable volume estimates can be made. Although LF MRI may not be able to depict image subtleties found at a HF level, ML tools available and in development allow for a higher resolution and SNR to be achieved from noisy LF images.^{e2}

Other limitations of pMRI are based on its physical properties. While the open geometry of the pMRI device is less confined than a cMRI bore, its small head coil and proximity to the magnets pose issues for some patients with claustrophobia. In addition to claustrophobia, the coil may also not accommodate patients with head circumferences exceeding the dimensions of the coil (26 cm wide and 20 cm high⁶), posing an obstacle for patients with larger heads, including children with hydrocephalus and associated macrocrania. In addition, a body weight of more than 200 kg may not be able to be positioned inside the device. Some nonportable LF MRI systems have been able to accommodate these shortcomings; for example, Synaptive's LF MRI has an adjustable head coil with a patient weight limit of approximately 250 kg.^{e3} In addition, pMRI's current average total scan time approximately ranges between 4 and 40 minutes, depending on sequences selected, which may be a limitation for patients who are claustrophobic or unstable for the time span of the scan. Sequence development and optimization is underway to shorten the scan time.

Future Opportunities

As pMRI develops alongside the current generation of medical trainees, concerted efforts should be made to familiarize trainees with this new technology. Future use of pMRI should capitalize on its accessibility and affordability to bring MRI

technology outside of traditional settings. With no need for a shielded room and no risk of radiation exposure, neuroimaging may even be brought into communities, increasing access with an emphasis on at-risk and disadvantaged populations. For example, pMRI may also benefit low-income and middle-income communities and countries where cMRIs are relatively inaccessible. Increasing neuroimaging in these areas will also cultivate opportunities for understanding brain development and neuropathology in varied settings.¹⁵ pMRI is currently commercially available in countries including the United States, Australia, and Pakistan and has been deployed in other areas including Germany and Malawi.^{e4} One group has successfully implemented pMRI in a low-resource setting: Queen Elizabeth Central Hospital in Malawi that aided in clinical guidance when CT was not available, expediting treatment management.^{e5}

Other resource-limited or time-sensitive contexts that may benefit from pMRI include sporting arenas, outpatient clinics, combat zones, and other settings where brain injury incidence is high and answering time-sensitive questions is imperative. In addition, through exploration in testing usage of LF strength MR for patients with programmable implants, pMRI can potentially expand the eligibility of patients who can receive MRI scans.

pMRI may one day play a vital role in acute neurologic settings, where timely neuroimaging is vital to coordinating rapid intervention. Mobile stroke units (MSUs) equipped with CT scanners allow for the ultra-rapid administration of intravenous tissue plasminogen activator in 72 minutes compared with standard of care of 108 minutes.^{e6} Equipping MSUs with pMRI in the place of CT could offer further benefits. Due to the use of DWI/T2-FLAIR mismatch as a marker of stroke onset, direct-to-MRI stroke care has shown to be useful in determining reperfusion therapies for strokes of unknown onset.^{e7} Based on its ICH specificity, pMRI could potentially serve as a tool in an MSU for reperfusion therapy selection.¹² The impact and application of pMRI will be further increased once contrast agents that can operate at low field have been developed.

In addition to envisioning settings in which pMRI may be useful, we also anticipate that the research community will start developing ML methods for an automated, reproducible analysis of LF scans, including segmentation of regions of interest for volumetric studies, registration of scans for longitudinal analysis, and segmentation of lesions for their characterization. Moreover, we foresee the development of ML domain adaptation techniques that will enable the application of methods developed for high-field images to LF scans.

Conclusion

Using LF magnetic strength, pMRI continues to enhance the field of neuroimaging by increasing accessibility. It circumvents the possible hazards of transporting patients by bringing imaging to the point of care for critically ill patients. With the ability to identify various neuropathologies, pMRI can aid clinicians by

supplementing conventional neuroimaging and by providing the benefits of rapid neuroimaging in resource-limited areas or time-sensitive circumstances where its value can be most impactful.

Study Funding

No targeted funding reported.

Disclosure

N.R. Parasuram, A.L. Crawford, M.H. Mazurek, I.R. Chavva, R. Beekman, E.J. Gilmore, N. Petersen, S. Payabvash, G. Sze, J. Eugenio Iglesias, S.B. Omay, C.C. Matouk, E.E. Longbrake, A. de Havenon, and S.J. Schiff report no disclosures relevant to the manuscript. M.S. Rosen is a founder and equity holder of Hyperfine, Inc. He currently receives grants from the AHA, NIH, and ARPA-E. M.S. Rosen acknowledges the support of the Kiyomi and Ed Baird MGH Research Scholar award. W.T. Kimberly receives grants from NIH and AHA. K.N. Sheth receives support from the Collaborative Science Award (American Heart Association), NIH Supplement Grant (U01NS106513-S1), and Hyperfine Research, Inc. research grant. Go to [Neurology.org/N](https://www.neurology.org/N) for full disclosures.

Publication History

Received by *Neurology* June 2, 2022. Accepted in final form January 4, 2023. Submitted and externally peer reviewed. The handling editor was Resident & Fellow Section Editor Whitley Aamodt, MD, MPH.

Appendix Authors

Name	Location	Contribution
Nethra R. Parasuram, BS	Department of Neurology, Yale University School of Medicine, New Haven, CT	Drafting/revision of the article for content, including medical writing for content
Anna L. Crawford, MS	Department of Neurology, Yale University School of Medicine, New Haven, CT	Drafting/revision of the article for content, including medical writing for content
Mercy H. Mazurek, BS	Department of Neurology, Yale University School of Medicine, New Haven, CT	Drafting/revision of the article for content, including medical writing for content
Isha R. Chavva, BS	Department of Neurology, Yale University School of Medicine, New Haven, CT	Drafting/revision of the article for content, including medical writing for content
Rachel Beekman, MD	Department of Neurology, Yale University School of Medicine, New Haven, CT	Drafting/revision of the article for content, including medical writing for content
Emily J. Gilmore, MD	Department of Neurology, Yale University School of Medicine, New Haven, CT	Drafting/revision of the article for content, including medical writing for content
Nils H. Petersen, MD	Department of Neurology, Yale University School of Medicine, New Haven, CT	Drafting/revision of the article for content, including medical writing for content
Syedmehtdi Payabvash, MD	Department of Radiology, Yale University School of Medicine, New Haven, CT	Drafting/revision of the article for content, including medical writing for content
Gordon Sze, MD, FACR	Department of Radiology, Yale University School of Medicine, New Haven, CT	Drafting/revision of the article for content, including medical writing for content

Appendix (continued)

Name	Location	Contribution
Juan Eugenio Iglesias, PhD	Computer Science and Artificial Intelligence Laboratory (CSAIL), Massachusetts Institute of Technology, Cambridge; Athinoula A. Martinos Center for Biomedical Imaging, Massachusetts General Hospital, Charlestown	Drafting/revision of the article for content, including medical writing for content
Sacit B. Omay, MD, FAANS	Department of Neurosurgery, Yale University School of Medicine, New Haven, CT	Drafting/revision of the article for content, including medical writing for content
Charles Matouk, MD	Department of Neurosurgery, Yale University School of Medicine, New Haven, CT	Drafting/revision of the article for content, including medical writing for content
Erin E. Longbrake, MD, PhD	Department of Neurology, Yale University School of Medicine, New Haven, CT	Drafting/revision of the article for content, including medical writing for content
Adam de Havenon, MD	Department of Neurology, Yale University School of Medicine, New Haven, CT	Drafting/revision of the article for content, including medical writing for content
Steven J. Schiff, MD, PhD	Department of Neurosurgery, Engineering Science and Mechanics, and Physics, The Pennsylvania State University, University Park	Drafting/revision of the article for content, including medical writing for content
Matthew S. Rosen, PhD	Athinoula A. Martinos Center for Biomedical Imaging, Massachusetts General Hospital, Charlestown	Drafting/revision of the article for content, including medical writing for content; obtained funding
W. Taylor Kimberly, MD, PhD	Division of Neurocritical Care, Department of Neurology, Massachusetts General Hospital, Boston	Drafting/revision of the article for content, including medical writing for content; study concept or design; obtained funding
Kevin N. Sheth, MD	Department of Neurology, Yale University School of Medicine, New Haven, CT	Drafting/revision of the article for content, including medical writing for content; study concept or design; obtained funding

References

- Hoeffner EG, Mukherji SK, Srinivasan A, Quint DJ. Neuroradiology back to the future: brain imaging. *Am J Neuroradiol*. 2012;33(1):5-11. doi:10.3174/ajnr.A2936.
- Algethamy HM, Alzawahmah M, Young GB, Mirsattari SM. Added value of MRI over CT of the brain in intensive care unit patients. *Can J Neurol Sci*. 2015;42(5):324-332. doi:10.1017/cjn.2015.52.
- Zimmerman RA, Bilaniuk L, Hackney D, Goldberg H, Grossman R. Head injury: early results of comparing CT and high-field MR. *Am J Roentgenol*. 1986;147(6):1215-1222. doi:10.2214/ajr.147.6.1215.
- Sarracanie M, LaPierre CD, Salameh N, Waddington DEJ, Witzel T, Rosen MS. Low-cost high-performance MRI. *Sci Rep*. 2015;5(1):15177. doi:10.1038/srep15177.
- Lovell MA, Mudaliar MY, Klineberg PL. Intrahospital transport of critically ill patients: complications and difficulties. *Anaesth Intensive Care*. 2001;29(4):400-405. doi:10.1177/0310057X0102900412.
- Prabhat AM, Crawford AL, Mazurek MH, et al. Methodology for low-field, portable magnetic resonance neuroimaging at the bedside. *Front Neurol*. 2021;12:760321. doi:10.3389/fneur.2021.760321.
- Brenner DJ, Hricak H. Radiation exposure from medical imaging: time to regulate? *JAMA*. 2010;304(2):208-209. doi:10.1001/jama.2010.973.
- Turpin J, Unadkat P, Thomas J, et al. Portable magnetic resonance imaging for ICU patients. *Crit Care Explor*. 2020;2(12):e0306. doi:10.1097/CCE.0000000000000306.

9. Sheth KN, Mazurek MH, Yuen MM, et al. Assessment of brain injury using portable, low-field magnetic resonance imaging at the bedside of critically ill patients. *JAMA Neurol.* 2021;78(1):41-47. doi:10.1001/jamaneurol.2020.3263.
10. Chavva IR, Mazurek MH, Yuen MM, et al. Deployment of portable, bedside, low-field magnetic resonance imaging in the emergency department to evaluate patients with acute stroke [abstract]. International Stroke Conference; February 9-11, 2022; New Orleans, LA. ISC; 2022. Abstract WP111.
11. Crawford A, Chavva IR, Mazurek MH, et al. Low-field portable magnetic resonance imaging in the operating room setting [abstract]. International Society for Magnetic Resonance in Medicine Workshop on Low Field MRI; March 17-18, 2022; Online. ISMRM; 2022.
12. Mazurek MH, Cahn BA, Yuen MM, et al. Portable, bedside, low-field magnetic resonance imaging for evaluation of intracerebral hemorrhage. *Nat Commun.* 2021; 12(1):S119. doi:10.1038/s41467-021-25441-6.
13. Sheth KN, Yuen MM, Mazurek MH, et al. Bedside detection of intracranial midline shift using portable magnetic resonance imaging. *Sci Rep.* 2022;12(1):67. doi:10.1038/s41598-021-03892-7.
14. Yuen MM, Prabhat AM, Mazurek MH, et al. Portable, low-field magnetic resonance imaging enables highly accessible and dynamic bedside evaluation of ischemic stroke. *Sci Adv.* 2022;8(16):eabm3952. doi:10.1126/sciadv.abm3952.
15. Deoni SCL, Bruchhage MMK, Beauchemin J, et al. Accessible pediatric neuroimaging using a low field strength MRI scanner. *Neuroimage.* 2021;238:118273. doi:10.1016/j.neuroimage.2021.118273.

eReferences e1–e13 are available at links.lww.com/WNL/C623.

The *Neurology*[®] Null Hypothesis Online Collection...

Contributing to a transparent research reporting culture!



The *Neurology* journals have partnered with the Center for Biomedical Research Transparency (CBMRT) to promote and facilitate transparent reporting of biomedical research by ensuring that all biomedical results—including negative and inconclusive results—are accessible to researchers and clinicians in the interests of full transparency and research efficiency.

Neurology's Null Hypothesis Collection is a dedicated online section for well conducted negative, inconclusive, or replication studies. View the collection at: NPub.org/NullHypothesis



Without Borders – A curated collection featuring advances in global neurology

This *Neurology*[®] special interest website is the go-to source for tracking science and politics of neurology beyond the United States, featuring up-to-the-minute blogs, scholarly perspectives, and academic review of developments and research from *Neurology* journals and other sources.

Expand your world view at Neurology.org/woborders.

Neurology[®]

Future of Neurology & Technology: Neuroimaging Made Accessible Using Low-Field, Portable MRI

Nethra R. Parasuram, Anna L. Crawford, Mercy H. Mazurek, et al.
Neurology 2023;100;1067-1071 Published Online before print January 31, 2023
DOI 10.1212/WNL.0000000000207074

This information is current as of January 31, 2023

Updated Information & Services	including high resolution figures, can be found at: http://n.neurology.org/content/100/22/1067.full
References	This article cites 13 articles, 1 of which you can access for free at: http://n.neurology.org/content/100/22/1067.full#ref-list-1
Subspecialty Collections	This article, along with others on similar topics, appears in the following collection(s): Clinical neurology examination http://n.neurology.org/cgi/collection/clinical_neurology_examination Critical care http://n.neurology.org/cgi/collection/critical_care Inclusion, Diversity, Equity, Anti-racism, and Social Justice (IDEAS) http://n.neurology.org/cgi/collection/all_equity_diversity_and_inclusion MRI http://n.neurology.org/cgi/collection/mri Prognosis http://n.neurology.org/cgi/collection/prognosis
Permissions & Licensing	Information about reproducing this article in parts (figures, tables) or in its entirety can be found online at: http://www.neurology.org/about/about_the_journal#permissions
Reprints	Information about ordering reprints can be found online: http://n.neurology.org/subscribers/advertise

Neurology® is the official journal of the American Academy of Neurology. Published continuously since 1951, it is now a weekly with 48 issues per year. Copyright © 2023 American Academy of Neurology. All rights reserved. Print ISSN: 0028-3878. Online ISSN: 1526-632X.

