

# Clinical Reasoning: A 25-Year-Old Woman With Eye Swelling and Headache

Aoife Hehir, MB, BCh, BAO, Ruth Gilmore, MB, BCh, BAO, Sarah Power, MB, BCh, BAO, Thomas Monaghan, MB, BCh, BAO,\* and Emer R. McGrath, MB, PhD\*

*Neurology*<sup>®</sup> 2023;100:879-883. doi:10.1212/WNL.0000000000206836

## Correspondence

Dr. Hehir  
a.hehir19@hotmail.com

## Abstract

Cerebral venous sinus thrombosis (CVST) is uncommon. Risk factors include inherited and acquired factors. Rapid diagnosis and treatment is essential and can help prevent complications, which can include seizures and visual disturbance. A 25-year-old woman with a background history of CVST and intermittent warfarin use presented to the hospital in 2021 with a 3-month history of progressive eye swelling and headache. Her headache was located in the right frontal region and worsened with movement. Her workup was consistent with recurrent CVST and dural arteriovenous fistula. IR-guided embolization of the fistulas and stenting of her sinuses was performed. She was treated with dual antiplatelet therapy and therapeutic tinzaparin. Her symptoms improved markedly over several days, with improvement in headache and visual acuity. This case illustrates the potential for severe complications including visual disturbance in untreated CVST, as well as the importance of a thorough history and examination in aiding the recognition of the condition.

---

\*These authors contributed equally to this work as joint senior authors.

From the Department of Neurology (A.H., T.M., E.R.M.), and Department of Hematology (R.G.), University Hospital, Galway; Department of Neuroradiology (S.P.), Beaumont Hospital, Dublin, Ireland; and HRB Clinical Research Facility Galway (E.R.M.), National University of Ireland Galway.

Go to [Neurology.org/N](https://www.neurology.org/N) for full disclosures. Funding information and disclosures deemed relevant by the authors, if any, are provided at the end of the article.

## Section 1

A 25-year-old woman presented to the hospital with a 3-month history of progressive right eye swelling and headache. She had a history of cerebral venous sinus thrombosis (CVST) in 2015 with recurrence in 2019 after which she was commenced on lifelong warfarin, having initially presented with headache and pulsatile tinnitus. In July 2020, she immigrated to Ireland and began intermittently taking warfarin. Her medical history was significant for a diagnosis of “idiopathic” intracranial hypertension in 2015, believed to be secondary to her previous CSVT. Acetazolamide had been commenced subsequently. Family history was notable for idiopathic venous thromboembolic disease in both parents.

Her headache was located in the right frontal area and exacerbated on lying down and moving, with no diurnal variation. It improved on sitting up. There was a sensation of right eye

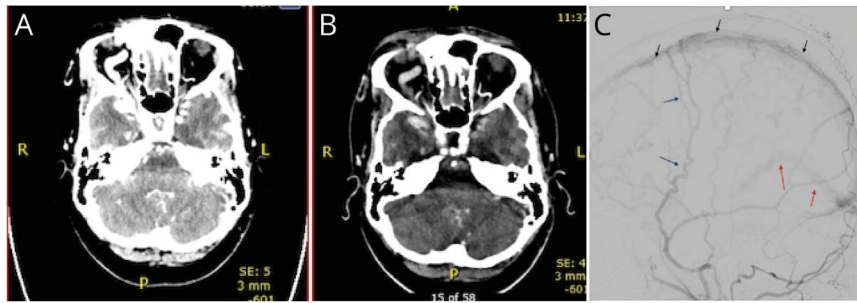
pressure. There was no history of fever, immunocompromise or infection, and no nausea, vomiting, or tinnitus.

Her vital signs were normal. Neurologic examination revealed gross right eye engorgement and proptosis, with no associated erythema or eye discharge. Visual acuity was 6/24 in the right eye and 6/6 in the left. A relative afferent pupillary defect (RAPD) was noted. Color vision was normal. She had impaired adduction and abduction in the right eye, with mild discomfort on adduction. Left eye movements were normal. Visual field testing revealed defects in the right eye (inferior and temporal regions predominantly) with sparing of the left. Fundoscopic examination was normal without evidence of optic disc swelling or pallor. The remainder of the neurologic examination was normal. Her international normalized ratio (INR) was 1.3 on presentation.

### Questions for Consideration:

1. What is the differential diagnosis?
2. What imaging should be considered?

**GO TO SECTION 2**



Axial CT venogram (A) and CT angiogram (B) show a dilated right ophthalmic vein with venous collaterals visible. (C) Lateral view of a right external carotid artery (ECA) angiogram, with early filling of the superior sagittal sinus in the arterial phase (black arrows) reflux to straight sinus and deep venous system (red arrows). Bilateral stenosis/occlusion of distal transverse sinus (absent filling of sigmoid and jugular bulb). Arterial supply from right ECA mainly through enlarged right middle meningeal artery (blue arrows).

## Section 2

The primary diagnosis to consider is recurrent CVST, given her symptoms, history of CVST, and intermittent warfarin use with a subtherapeutic INR. Other differentials include a right orbitopathy due to Grave disease (although thyroid function tests were normal) or another compressive, infiltrative, or inflammatory process (e.g. orbital pseudotumor, sarcoidosis, lymphoma, or metastases), which could explain the RAPD, reduced vision, and restricted adduction and abduction confined to the right eye. Pathology in the cavernous sinus, including infectious, inflammatory, or infiltrative processes (e.g. the Tolosa Hunt syndrome, cavernous sinus thrombosis secondary to infection, or immunoglobulin G4 disease) could also be considered. Finally, a carotid cavernous sinus fistula, while rare, should also be considered. The prolonged nature of her symptoms and gradual onset of proptosis suggested a subacute or chronic process rather than an acute disorder.

Given impaired adduction and abduction of her right eye, pathology within the cavernous sinus affecting the right oculomotor and abducens nerves was considered. The absence of left eye visual disturbance suggested pathology at the level

of, or anterior to, the right optic chiasm. The optic nerve does not traverse but passes superomedially to the cavernous sinus, and thus, cavernous sinus pathology could theoretically cause secondary visual disturbance.

In a patient with suspected CVST, imaging with MRI brain and MR venography or CT brain with CT venography should be performed. Our patient underwent CT of the orbits and sinuses and CT cerebral angiogram and venogram as part of the additional workup (Figure). Right-sided exophthalmos was noted with right cavernous sinus dilation with surrounding extensive venous collateralization. Filling defects were present in the right jugular vein, sigmoid sinus, and right transverse sinus, consistent with CVST. In addition, the right ophthalmic vein was markedly dilated. There were no solid mass lesions or extraocular muscle abnormalities and no abnormal contrast enhancement indicative of a carotid cavernous fistula.

### Questions for Consideration:

1. What are the risk factors for CVST?
2. How may her imaging findings explain her symptoms?
3. What further imaging should be considered?

GO TO SECTION 3

## Section 3

The risk factors for CVST (Table) include inherited or acquired prothrombotic conditions, including hematologic conditions, pregnancy, oral contraceptive pill use, and malignancy.<sup>1</sup> Our patient had stopped using the oral contraceptive pill after her initial CVST.

Thrombosis of the venous sinuses or dural veins leads to obstruction causing increased venous and capillary pressure and alteration of the blood-brain barrier. The subsequent reduction in CSF absorption causes increased intracranial pressure (ICP).

The increased venous pressure can cause compensatory cerebral vein dilatation and formation of collaterals. In our patient's case, dilation of the ophthalmic vein along with venous collateralization likely led to the significant exophthalmos and restriction of right eye movements we observed. Although our patient had no evidence of papilledema or optic disc swelling on examination, her ongoing headache which was exacerbated on lying down and with a sensation of pressure behind her eyes was likely related to some component of elevated ICP.

She was transferred to a hospital with specialist NeuroRadiology services and underwent digital subtraction angiography (DSA), which revealed extensive dural arteriovenous fistulas (dAVFs) involving the superior sagittal sinus and the junction of the right transverse and sigmoid sinuses. Delayed venous outflow from the fistulas and from normal brain parenchyma was noted.

dAVFs are abnormal, direct communications between the intracranial arterial and venous systems.<sup>2</sup> A common risk factor for their development is an underlying venous sinus thrombosis.

**Table** Causes of Cerebral Venous Sinus Thrombosis

Inherited	Acquired
Inflammatory diseases	Pregnancy/puerperium
Systemic lupus erythematosus	Dehydration
Behcet disease	Drugs
Thromboangiitis obliterans	Oral contraceptives
Inflammatory bowel disease	Hormone replacement therapy
Hematologic conditions	Mechanical precipitants
Factor V Leiden mutation	Head injury
Protein C deficiency	Infection
Protein S deficiency	CNS infection
Antithrombin III deficiency	Sinus infection
Antiphospholipid antibody syndrome	Malignancy
G20210 A prothrombin gene mutation	Nephrotic syndrome

A recent study found a 2.4% occurrence of dAVF in patients with CVST, with a higher incidence in those with chronic CVST onset, male gender, and increasing age.<sup>3</sup> This is in contrast to our young female patient.

Thrombosis leads to venous hypertension, thus opening microvascular connections in the dura,<sup>4</sup> which can become enlarged causing development of direct shunting between arteries and veins. The gold standard imaging of choice for visualizing dAVFs is DSA (Figure), allowing the assessment of feeding vessels and for planning intervention.<sup>2</sup>

Our patient underwent IR-guided embolization of the dAVFs along with stenting of the right distal transverse and sigmoid sinuses to maintain venous patency. She was commenced on dual antiplatelet therapy to prevent in-stent thrombosis, along with subcutaneous therapeutic tinzaparin for the management of CVST. She experienced transient shortness of breath and underwent CTPA, which was negative for pulmonary embolus. Her remaining postoperative course was uneventful aside from mild positional headache.

## Discussion

CVST is uncommon, with an incidence of 1.57/100,000, and more commonly affects women (female-to-male ratio of 3:1).<sup>5</sup> In the most adult patients, at least 1 risk factor can be identified, predominantly acquired prothrombotic conditions, such as pregnancy or malignancy.<sup>1</sup>

The cause of her CVST was investigated. At the time of her previous presentations, she was investigated with cerebral CT angiography and MR venography. On this admission, thrombophilia screening was performed, with normal protein C, protein S, and antithrombin levels. Antiphospholipid antibody, paroxysmal nocturnal hemoglobinuria screening, and JAK2 mutation were negative. LDH was normal. Serum immunoglobulins were within the normal range, and electrophoresis showed no monoclonal band. Follow-up imaging in mid-2020 showed minimal residual thrombosis, with dilated meningeal veins particularly in the middle cranial fossa. The cause for her initial CVST remains unknown.

After a hematologic review, the etiology for the thromboses in both parents was believed to be most likely due to major independent risk factors for thrombosis, as opposed to a familial hypercoagulable disorder.

The most patients with CVST present with new-onset headache, with or without an intracranial hypertension syndrome, along with focal neurologic deficits, seizures, or encephalopathy. Management involves anticoagulation in the acute phase. The current European guidelines recommend the use of therapeutic dose heparin. Patients are typically transitioned to oral anticoagulation after the acute phase, which should be continued for a minimum of 3 months. Our patient was commenced on dual

antiplatelet therapy with aspirin and clopidogrel for 3 months, with a plan to switch to aspirin monotherapy given her recent stenting—as well as subcutaneous tinzaparin. There was a plan to switch to lifelong oral anticoagulation thereafter.

Although there is no definitive evidence regarding the optimal length of anticoagulation therapy specifically for lowering the risk of recurrent CVST,<sup>1</sup> indefinite anticoagulation may be required if recurrent CVST. Regarding the selection of anticoagulation agent, the RE-SPECT CVST trial showed similar effectiveness and safety for warfarin and dabigatran in the prevention of recurrent CVST.<sup>6</sup>

Given the extent of thrombosis and dAVFs visible on our patient's imaging, it was difficult to appreciate how these findings had developed over the 3 months between onset of symptoms and presentation. Her previous brain imaging reports from 2020 to 2018 were reviewed, and although no dAVFs were reported, there were venous changes noted in early 2020. However, right eye involvement was not markedly apparent until imaging in January 2021 (Figure). Thus, we felt it was likely that further thrombosis occurred after our patient's move to Ireland in mid-2020 leading to her symptoms and ultimate presentation.

Our patient progressed well after stenting and embolization. Right-sided headache initially remained an issue. Her acetazolamide had been held given its prothrombotic effects but was recommenced after worsening of headache, with improvement noted. Ophthalmology input was sought, and marked improvement in eye movements was noted in the days after stenting and embolization. After several days, she was discharged with plan for hematology and neurology follow-up, and repeat imaging subsequently.

## Acknowledgment

The authors acknowledge the contribution of Dr. Paul Brennan, LRCP & SI MB BCh NUI (Department of Neuroradiology, Beaumont Hospital, Dublin, Ireland) who reported on some of the radiological investigations mentioned in this case report and whose contributions qualified him for authorship in this case report. Unfortunately, although a thorough search was carried out, he could not be contacted to sign the required authorship forms. Should he be contacted or should he see this notice, Dr. Brennan will be given every opportunity to sign the necessary legal forms, at which point, the byline of this report will be corrected to include his name. The corresponding and senior authors report that no disclosures relevant to the manuscript are known to be had by Dr. Brennan.

## Study Funding

No targeted funding reported.

## Disclosure

The authors report no relevant disclosures. Go to Neurology.org/N for full disclosures.

## Publication History

Received by *Neurology* October 17, 2021. Accepted in final form December 6, 2022. Submitted and externally peer reviewed. The handling editor was Resident and Fellow Section Editor Whitley Aamodt, MD, MPH.

## Appendix Authors

Name	Location	Contribution
<b>Aoife Hehir, MB, BCh, BAO</b>	Department of Neurology, University Hospital, Galway, Ireland	Drafting/revision of the manuscript for content, including medical writing for content; major role in the acquisition of data
<b>Ruth Gilmore, MB, BCh, BAO</b>	Department of Hematology, University Hospital, Galway, Ireland	Drafting/revision of the manuscript for content, including medical writing for content
<b>Sarah Power, MB, BCh, BAO</b>	Department of Neuroradiology, Beaumont Hospital, Dublin, Ireland	Drafting/revision of the manuscript for content, including medical writing for content
<b>Thomas Monaghan, MB, BCh, BAO</b>	Department of Neurology, University Hospital, Galway, Ireland	Drafting/revision of the manuscript for content, including medical writing for content
<b>Emer R. McGrath, MB, PhD</b>	Department of Neurology, University Hospital, Galway, Ireland; HRB Clinical Research Facility Galway, National University of Ireland Galway	Drafting/revision of the manuscript for content, including medical writing for content; analysis or interpretation of data

## References

1. Ferro JM, Boussier MG, Canhão P, et al; European Stroke Organization. European Stroke Organization guideline for the diagnosis and treatment of cerebral venous thrombosis: endorsed by the European Academy of Neurology. *Eur J Neurol*. 2017; 24(10):1203-1213. doi:10.1111/ene.13381.
2. Gupta A, Periakaruppan A. Intracranial dural arteriovenous fistulas: a Review. *Indian J Radiol Imaging*. 2009;19(1):43-48. doi:10.4103/0971-3026.45344.
3. Lindgren E, Rentzos A, Hiltunen S, et al; International CVT Consortium. Dural arteriovenous fistulas in cerebral venous thrombosis: data from the International Cerebral Venous Thrombosis Consortium. *Eur J Neurol*. 2022;29(3):761-770. doi:10.1111/ene.15192.
4. Houser O, Campbell J, Campbell R, Sundt I. Arteriovenous malformation affecting the transverse dural venous sinus: an acquired lesion. *Mayo Clin Proc*. 1979;54(10):651-661.
5. Coutinho J, Ferro J, Canhão P, et al. Cerebral venous and sinus thrombosis in women. *Stroke*. 2009;40(7):2356-2361. doi:10.1161/STROKEAHA.108.543884.
6. Ferro J, Coutinho J, Dentali F, et al. Safety and efficacy of dabigatran etexilate vs dose-adjusted warfarin in patients with cerebral venous thrombosis. *JAMA Neurol*. 2019;76(12):1457-1465. doi:10.1001/jamaneurol.2019.2764.

# Neurology<sup>®</sup>

## **Clinical Reasoning: A 25-Year-Old Woman With Eye Swelling and Headache**

Aoife Hehir, Ruth Gilmore, Sarah Power, et al.

*Neurology* 2023;100;879-883 Published Online before print January 25, 2023

DOI 10.1212/WNL.0000000000206836

**This information is current as of January 25, 2023**

<b>Updated Information &amp; Services</b>	including high resolution figures, can be found at: <a href="http://n.neurology.org/content/100/18/879.full">http://n.neurology.org/content/100/18/879.full</a>
<b>References</b>	This article cites 6 articles, 1 of which you can access for free at: <a href="http://n.neurology.org/content/100/18/879.full#ref-list-1">http://n.neurology.org/content/100/18/879.full#ref-list-1</a>
<b>Subspecialty Collections</b>	This article, along with others on similar topics, appears in the following collection(s): <b>All Clinical Neurology</b> <a href="http://n.neurology.org/cgi/collection/all_clinical_neurology">http://n.neurology.org/cgi/collection/all_clinical_neurology</a> <b>All Headache</b> <a href="http://n.neurology.org/cgi/collection/all_headache">http://n.neurology.org/cgi/collection/all_headache</a> <b>Cerebral venous thrombosis</b> <a href="http://n.neurology.org/cgi/collection/cerebral_venous_thrombosis">http://n.neurology.org/cgi/collection/cerebral_venous_thrombosis</a> <b>Hematologic</b> <a href="http://n.neurology.org/cgi/collection/hematologic">http://n.neurology.org/cgi/collection/hematologic</a>
<b>Permissions &amp; Licensing</b>	Information about reproducing this article in parts (figures, tables) or in its entirety can be found online at: <a href="http://www.neurology.org/about/about_the_journal#permissions">http://www.neurology.org/about/about_the_journal#permissions</a>
<b>Reprints</b>	Information about ordering reprints can be found online: <a href="http://n.neurology.org/subscribers/advertise">http://n.neurology.org/subscribers/advertise</a>

*Neurology*® is the official journal of the American Academy of Neurology. Published continuously since 1951, it is now a weekly with 48 issues per year. Copyright © 2023 American Academy of Neurology. All rights reserved. Print ISSN: 0028-3878. Online ISSN: 1526-632X.

