

Teaching Video NeuroImage: Reverse Ocular Bobbing as a Presenting Feature of Brainstem Cavernoma

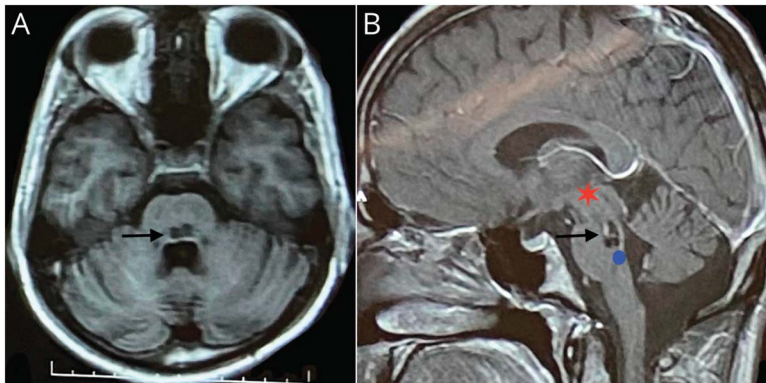
Kavindra Singh, MBBS, MS, MCh, and Pravin Salunke, MBBS, MS, MCh

Neurology® 2023;100:685-686. doi:10.1212/WNL.000000000206756

Correspondence

Dr. Singh
singh.kavindra8@gmail.com

Figure Axial and Sagittal MRIs Delineating a Dorsal Pontine Cavernoma



(A) T1-weighted axial MRI sequence showing a hypointense lesion in dorsal pons (marked with black arrow). (B) T1W+C sagittal MRI sequence depicting a lesion (marked with black arrow) with faint contrast enhancement at dorsal pontomesencephalic junction. Red star represents riMLF, which has the excitatory burst neurons for vertical saccades, and blue circle at dorsal pons approximates location of omnipause cells lying in the nucleus raphe interpositus, which is located in the midline at the level of abducens nucleus. The connections between riMLF and omnipause neurons are damaged leading to reverse bobbing. riMLF = rostral interstitial nucleus of the medial longitudinal fasciculus.

A 21-year-old man presented with oscillopsia, repetitive eye blinking, and headache for 20 days. He had intact vision with normal pupillary reaction. Although the horizontal and vertical gazes were intact, there were abnormal conjugate vertical movements with quick up phase followed by slow return to midposition suggestive of reverse ocular bobbing (Video 1). Bobbing was present in all directions of gaze and was associated with synkinetic lid movements. Imaging suggested a dorsal pontine cavernoma (Figure). The patient opted for radiosurgery. Omnipause neurons in dorsal pons tonically inhibit the rostral interstitial nucleus of the medial longitudinal fasciculus burst neurons (center for vertical saccades) which also indirectly stimulates levator subnucleus.¹ Damage to omnipause neurons or connections may cause reverse ocular bobbing with synkinetic lid movements. Unlike ocular bobbing, the horizontal gaze is intact because of uninvolved paramedian pontine reticular formation.² Interestingly, reverse ocular bobbing has been previously reported in cases of metabolic encephalopathy but is rarely associated with a structural lesion.

Author Contributions

K. Singh: drafting/revision of the manuscript for content, including medical writing for content; major role in the acquisition of data. P. Salunke: drafting/revision of the manuscript

MORE ONLINE

▶ Video

Teaching slides

<http://links.lww.com/WNL/C579>

From the Department of Neurosurgery, Post Graduate Institute of Medical Education and Research, Chandigarh, India.

Go to Neurology.org/N for full disclosures. Funding information and disclosures deemed relevant by the authors, if any, are provided at the end of the article.

for content, including medical writing for content; study concept or design; analysis or interpretation of data.

Study Funding

No targeted funding reported.

Disclosure

The authors report no relevant disclosures. Go to [Neurology.org/N](https://www.neurology.org/N) for full disclosures.

Publication History

Received by *Neurology* August 22, 2022. Accepted in final form November 16, 2022. Submitted and externally peer reviewed. The handling editor was Resident and Fellow Section Editor Whitley Aamodt, MD, MPH.

References

1. Brazis PW. The localization of lesions affecting the ocular motor system. In: Brazis PW, Masdeu JC, Biller J, eds. *Localization in Clinical Neurology*, 6th ed. Lippincott Williams & Wilkins, 2011:173-304.
2. Munakomi S, Thapa L. Seesaw-pattern ocular bobbing in a patient with pontine bleed. *JAMA Neurol*. 2019;76(3):362-363. doi:10.1001/jamaneurol.2018.3853.



Practice Current: An interactive exchange on controversial topics

Share your own best practices.
Read commentary with expert opinion.
Explore results on an interactive world map.

[NPub.org/NCP/practicecurrent](https://www.npub.org/NCP/practicecurrent)

Neurology[®] Clinical Practice



Without Borders – A curated collection featuring advances in global neurology

This *Neurology*[®] special interest website is the go-to source for tracking science and politics of neurology beyond the United States, featuring up-to-the-minute blogs, scholarly perspectives, and academic review of developments and research from *Neurology* journals and other sources.

Expand your world view at [Neurology.org/woborders](https://www.neurology.org/woborders).

Neurology[®]

Teaching Video NeuroImage: Reverse Ocular Bobbing as a Presenting Feature of Brainstem Cavernoma

Kavindra Singh and Pravin Salunke

Neurology 2023;100:685-686 Published Online before print December 29, 2022

DOI 10.1212/WNL.0000000000206756

This information is current as of December 29, 2022

Updated Information & Services	including high resolution figures, can be found at: http://n.neurology.org/content/100/14/685.full
References	This article cites 1 articles, 0 of which you can access for free at: http://n.neurology.org/content/100/14/685.full#ref-list-1
Subspecialty Collections	This article, along with others on similar topics, appears in the following collection(s): All Clinical Neurology http://n.neurology.org/cgi/collection/all_clinical_neurology All Education http://n.neurology.org/cgi/collection/all_education All Neuro-ophthalmology http://n.neurology.org/cgi/collection/all_neuroophthalmology Ocular motility http://n.neurology.org/cgi/collection/ocular_motility Oscillopsia http://n.neurology.org/cgi/collection/oscillopsia
Permissions & Licensing	Information about reproducing this article in parts (figures, tables) or in its entirety can be found online at: http://www.neurology.org/about/about_the_journal#permissions
Reprints	Information about ordering reprints can be found online: http://n.neurology.org/subscribers/advertise

Neurology® is the official journal of the American Academy of Neurology. Published continuously since 1951, it is now a weekly with 48 issues per year. Copyright © 2022 American Academy of Neurology. All rights reserved. Print ISSN: 0028-3878. Online ISSN: 1526-632X.

