

---

**Neurology Publish Ahead of Print**  
**DOI:10.1212/WNL.0000000000207095**

Teaching NeuroImage: Imaging and Pathologic Findings in SARS-CoV-2–Related Acute  
Demyelinating Encephalomyelitis

**Author(s):**

Rakhee Lalla, DO<sup>1</sup>; Ramya Narasimhan, MD<sup>2</sup>; Mohamad Abdalkader, MD<sup>3</sup>; Deepti Virmani, MD<sup>1</sup>; Kushak Suchdev, MD<sup>1,4</sup>; Brian Moore, MD, MEd<sup>2</sup>; Anna Cervantes-Arslanian, MD<sup>1,4,5</sup>

**Corresponding Author:**

Anna Cervantes-Arslanian, anna.cervantes@bmc.org

**Affiliation Information for All Authors:** 1. Department of Neurology, Boston University School of Medicine and Boston Medical Center, Boston, MA; 2. Department of Pathology, Boston University School of Medicine and Boston Medical Center, Boston, MA; 3. Department of Radiology, Boston University School of Medicine and Boston Medical Center, Boston, MA; 4. Department of Neurosurgery, Boston University School of Medicine and Boston Medical Center, Boston, MA; 5. Department of Medicine (Infectious disease), Boston University School of Medicine and Boston Medical Center, Boston, MA

**Equal Author Contribution:**

*Neurology*® Published Ahead of Print articles have been peer reviewed and accepted for publication. This manuscript will be published in its final form after copyediting, page composition, and review of proofs. Errors that could affect the content may be corrected during these processes.

**Contributions:**

Rakhee Lalla: Drafting/revision of the manuscript for content, including medical writing for content; Major role in the acquisition of data; Study concept or design; Analysis or interpretation of data

Ramya Narasimhan: Drafting/revision of the manuscript for content, including medical writing for content; Major role in the acquisition of data

Mohamad Abdalkader: Drafting/revision of the manuscript for content, including medical writing for content; Major role in the acquisition of data

Deepti Virmani: Study concept or design

Kushak Suchdev: Drafting/revision of the manuscript for content, including medical writing for content

Brian Moore: Drafting/revision of the manuscript for content, including medical writing for content; Major role in the acquisition of data; Study concept or design; Analysis or interpretation of data

Anna Cervantes-Arslanian: Drafting/revision of the manuscript for content, including medical writing for content; Major role in the acquisition of data; Study concept or design; Analysis or interpretation of data

**Figure Count:**

2

**Table Count:**

0

**Search Terms:**

[ 44 ] Acute disseminated encephalomyelitis, [ 120 ] MRI, [ 360 ] COVID-19, [ 145 ] Post-infectious, Pathology

**Acknowledgment:****Study Funding:**

The authors report no targeted funding

**Disclosures:**

The authors report no disclosures relevant to the manuscript.

**Preprint DOI:****Received Date:**

2022-07-06

**Accepted Date:**

2023-01-10

**Handling Editor Statement:**

Submitted and externally peer reviewed. The handling editor was Resident and Fellow Deputy Editor Ariel Lyons-Warren, MD, PhD.

**Case:**

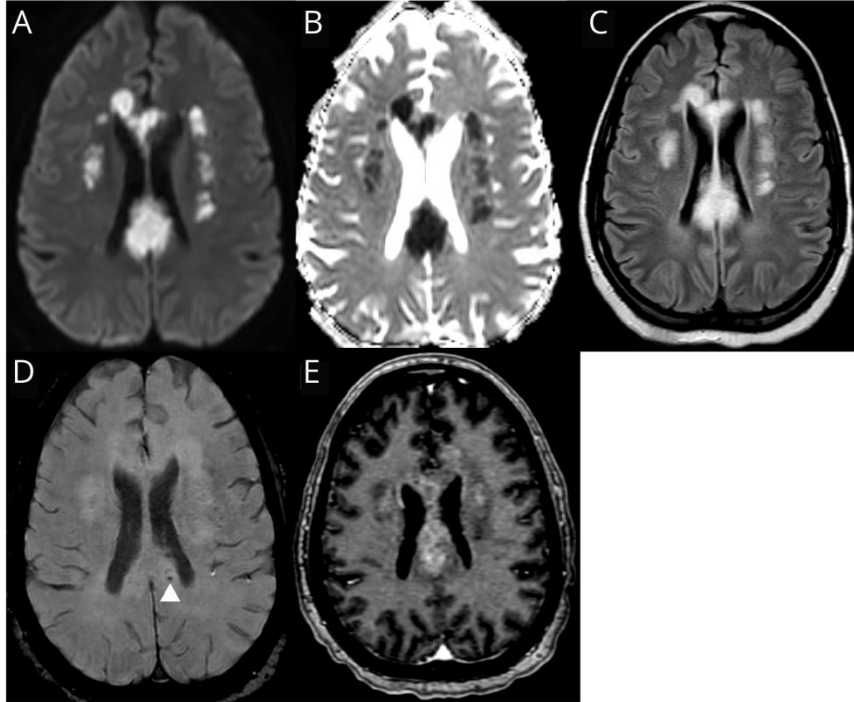
A 41-year-old woman with type 1 diabetes admitted with SARS-CoV-2 PCR confirmed respiratory failure developed altered mental status. EEG was unrevealing and CSF showed an elevated protein (110 mg/dL), normal glucose (159 mg/dL), without pleocytosis or oligoclonal bands and normal IgG index. MRI demonstrated FLAIR hyperintensities in the corpus callosum and periventricular white matter (**Figure 1**). She was treated with plasmapheresis for presumed SARS-CoV-2 related acute demyelinating encephalomyelitis (ADEM) but succumbed to cardiopulmonary arrest. Post-mortem histology revealed irregular zones of demyelination with axonal sparing and perivascular inflammatory infiltrate, consistent with ADEM (**Figure 2**). There was no inflammation within the vessel walls as is seen in vasculitis. SARS-CoV-2 ADEM has variable clinical presentations. Involvement of deep white matter and the corpus callosum have been previously reported, as well as hemorrhagic leukoencephalopathy, though only minimal microhemorrhage was present for this patient.<sup>1</sup> ADEM can be difficult to diagnose, and outcomes are often poor.<sup>2</sup>

1. Reichard RR, Kashani KB, Boire NA, Constantopoulos E, Guo Y, Lucchinetti CF. Neuropathology of COVID-19: a spectrum of vascular and acute disseminated encephalomyelitis (ADEM)-like pathology. *Acta Neuropathol.* 2020;140(1):1-6. doi:10.1007/s00401-020-02166-2
2. Wang Y, Wang Y, Huo L, Li Q, Chen J, Wang H. SARS-CoV-2-associated acute disseminated encephalomyelitis: a systematic review of the literature. *J Neurol.* 2022;269(3):1071-1092. doi:10.1007/s00415-021-10771-8

ACCEPTED

**Figure 1: MRI brain with contrast:**

Diffusion weighted image (A) with Apparent Diffusion Coefficient (ADC) (B) showing confluent areas of restricted diffusion with associated FLAIR hyperintensity (C) involving the corpus callosum and bilateral corona radiata. Microhemorrhages (D) in the corpus callosum. Post contrast images (E) demonstrate heterogeneous enhancement.



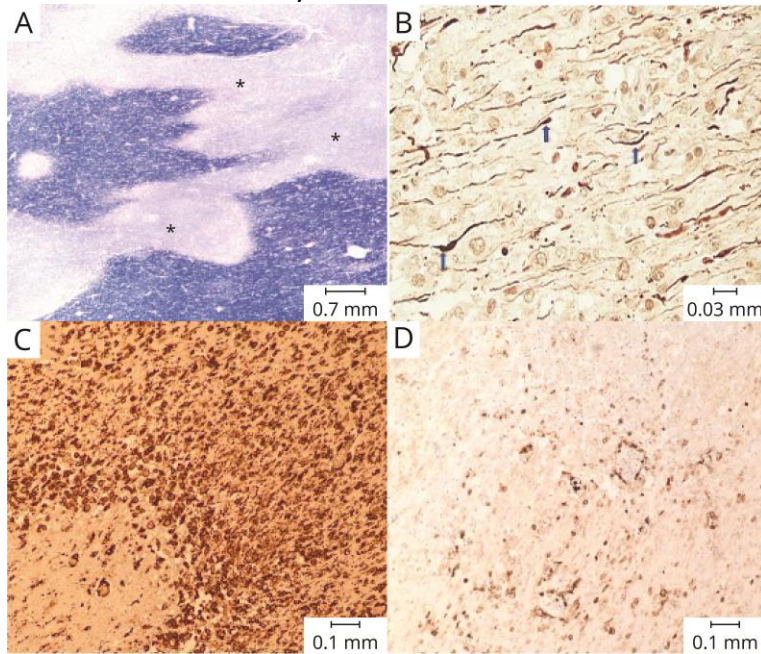
**Figure 2: Post-mortem histology from the splenium of the corpus callosum.**

(A): Areas of pallor representing demyelination (\*) on Luxol Fast Blue stain

(B): Relative preservation of axons (blue arrows), shown by neurofilament immunohistochemistry

(C): Dense macrophage infiltration as evidenced by CD163 immunohistochemistry

(D): Scattered lymphocytic infiltration as demonstrated by leukocyte common antigen immunohistochemistry



# Neurology<sup>®</sup>

## Teaching NeuroImage: Imaging and Pathologic Findings in SARS-CoV-2–Related Acute Demyelinating Encephalomyelitis

Rakhee Lalla, Ramya Narasimhan, Mohamad Abdalkader, et al.

*Neurology* published online February 16, 2023

DOI 10.1212/WNL.0000000000207095

**This information is current as of February 16, 2023**

<b>Updated Information &amp; Services</b>	including high resolution figures, can be found at: <a href="http://n.neurology.org/content/early/2023/02/16/WNL.0000000000207095.citation.full">http://n.neurology.org/content/early/2023/02/16/WNL.0000000000207095.citation.full</a>
<b>Subspecialty Collections</b>	This article, along with others on similar topics, appears in the following collection(s): <b>Acute disseminated encephalomyelitis</b> <a href="http://n.neurology.org/cgi/collection/acute_disseminated_encephalomyelitis">http://n.neurology.org/cgi/collection/acute_disseminated_encephalomyelitis</a>  <b>COVID-19</b> <a href="http://n.neurology.org/cgi/collection/covid_19">http://n.neurology.org/cgi/collection/covid_19</a> <b>MRI</b> <a href="http://n.neurology.org/cgi/collection/mri">http://n.neurology.org/cgi/collection/mri</a> <b>Post-infectious</b> <a href="http://n.neurology.org/cgi/collection/postinfectious_">http://n.neurology.org/cgi/collection/postinfectious_</a>
<b>Permissions &amp; Licensing</b>	Information about reproducing this article in parts (figures, tables) or in its entirety can be found online at: <a href="http://www.neurology.org/about/about_the_journal#permissions">http://www.neurology.org/about/about_the_journal#permissions</a>
<b>Reprints</b>	Information about ordering reprints can be found online: <a href="http://n.neurology.org/subscribers/advertise">http://n.neurology.org/subscribers/advertise</a>

*Neurology*® is the official journal of the American Academy of Neurology. Published continuously since 1951, it is now a weekly with 48 issues per year. Copyright © 2023 American Academy of Neurology. All rights reserved. Print ISSN: 0028-3878. Online ISSN: 1526-632X.

