

Neurology®

The most widely read and highly cited peer-reviewed neurology journal
The Official Journal of the American Academy of Neurology



Neurology Publish Ahead of Print
DOI: 10.1212/WNL.000000000206751

Teaching NeuroImage: Palmaris Brevis Sign: Clue to Localizing Ulnar Nerve Neuropathy

Author(s):

Vasudeva G Iyer, MD¹

Corresponding Author:

Vasudeva G Iyer, pavaiyer@gmail.com

Affiliation Information for All Authors: 1. Neurodiagnostic Center, Louisville, KY

Neurology® Published Ahead of Print articles have been peer reviewed and accepted for publication. This manuscript will be published in its final form after copyediting, page composition, and review of proofs. Errors that could affect the content may be corrected during these processes.

Equal Author Contribution:

Contributions:

Vasudeva G Iyer: Drafting/revision of the manuscript for content, including medical writing for content; Major role in the acquisition of data; Study concept or design; Analysis or interpretation of data

Figure Count:

1

Table Count:

0

Search Terms:

[16] Clinical neurology examination, [265] Peripheral nerve trauma, Guyon's canal, Palmaris brevis sign, Ulnar nerve

Acknowledgment:

Study Funding:

The authors report no targeted funding

Disclosures:

V. G. Iyer reports no disclosures relevant to this manuscript.

Preprint DOI:**Received Date:**

2022-08-14

Accepted Date:

2022-11-15

Handling Editor Statement:

Submitted and externally peer reviewed. The handling editor was Whitley Aamodt, MD, MPH.

Case:

A 65-year-old male sustained penetrating injury to the base of the hypothenar area from a slipped drill bit. Severe weakness of ulnar nerve-innervated intrinsic hand muscles was noted with normal sensations in digits 4 and 5. Attempt at abduction of small finger against resistance caused puckering of skin from contraction of palmaris brevis (Figure, A).

In ulnar nerve injuries at the Guyon's canal, intact contraction of palmaris brevis localizes the injury to site 2 (Figure, B) *distal* to the origin of the superficial branch of the ulnar nerve (which in addition to carrying sensations from digit 5 and ulnar side of digit 4 also provides motor innervation to palmaris brevis). This finding has been previously referred to as palmaris brevis sign.^{1,2}

Nerve conduction and EMG studies in this patient confirmed the location of ulnar nerve injury to site 2 at the Guyon's canal.

<http://links.lww.com/WNL/C560>

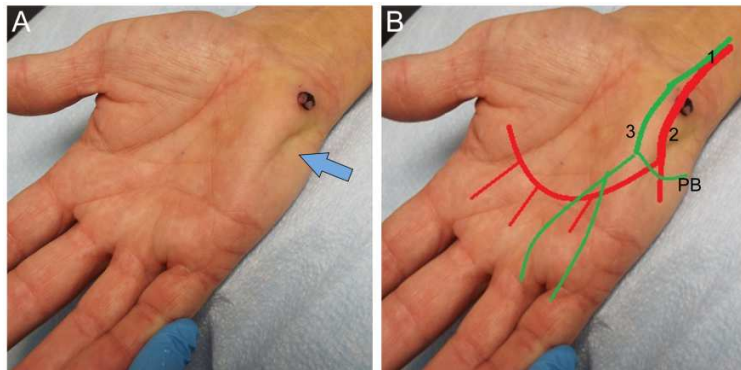
References:

1. Pleet AB, Massey EW. Palmaris brevis sign in neuropathy of the deep palmar branch of the ulnar nerve. *Ann Neurol.* 1978;3(5):468-469
2. Iyer V. Palmaris brevis sign in ulnar neuropathy. *Muscle & Nerve.* 1998;21(5):675-677

Figure 1. Ulnar nerve injury at Guyon's canal: Localization

A: Puckering of skin (arrow) from normal contraction of palmaris brevis muscle. Note scar from drill bit injury.

B: Guyon's canal lesions at site 2 involve deep motor (Red), but spare superficial sensory (Green) branch of the ulnar nerve, which innervates palmaris brevis (PB). Lesions at sites 1 and 3 paralyze PB.



Neurology[®]

Teaching NeuroImage: Palmaris Brevis Sign: Clue to Localizing Ulnar Nerve Neuropathy

Vasudeva G Iyer

Neurology published online December 20, 2022

DOI 10.1212/WNL.0000000000206751

This information is current as of December 20, 2022

Updated Information & Services	including high resolution figures, can be found at: http://n.neurology.org/content/early/2022/12/20/WNL.0000000000206751.citation.full
Subspecialty Collections	This article, along with others on similar topics, appears in the following collection(s): Clinical neurology examination http://n.neurology.org/cgi/collection/clinical_neurology_examination Peripheral nerve trauma http://n.neurology.org/cgi/collection/peripheral_nerve_trauma
Permissions & Licensing	Information about reproducing this article in parts (figures, tables) or in its entirety can be found online at: http://www.neurology.org/about/about_the_journal#permissions
Reprints	Information about ordering reprints can be found online: http://n.neurology.org/subscribers/advertise

Neurology® is the official journal of the American Academy of Neurology. Published continuously since 1951, it is now a weekly with 48 issues per year. Copyright © 2022 American Academy of Neurology. All rights reserved. Print ISSN: 0028-3878. Online ISSN: 1526-632X.

