

Neurology[®]

The most widely read and highly cited peer-reviewed neurology journal
The Official Journal of the American Academy of Neurology



Neurology Publish Ahead of Print

DOI: 10.1212/WNL.000000000201700

Pearls & Oysters: Trigeminal Cystic Schwannoma Presenting With Foster Kennedy Syndrome, Sixth Nerve Palsy, and Focal Seizures

Author(s):

Yasamin Mahjoub, MD¹; Miranda Wan, MD¹; Suresh Subramaniam, MD^{1,2}

Corresponding Author:

Yasamin Mahjoub, ymahjoub@ucalgary.ca

Affiliation Information for All Authors: 1. Department of Clinical Neurosciences, University of Calgary, Canada; 2. Department of Surgery, University of Calgary, Canada

Equal Author Contribution:

Neurology[®] Published Ahead of Print articles have been peer reviewed and accepted for publication. This manuscript will be published in its final form after copyediting, page composition, and review of proofs. Errors that could affect the content may be corrected during these processes.

Contributions:

Yasamin Mahjoub: Drafting/revision of the manuscript for content, including medical writing for content; Major role in the acquisition of data; Analysis or interpretation of data

Miranda Wan: Drafting/revision of the manuscript for content, including medical writing for content; Major role in the acquisition of data; Analysis or interpretation of data

Suresh Subramaniam: Drafting/revision of the manuscript for content, including medical writing for content; Major role in the acquisition of data; Study concept or design; Analysis or interpretation of data

Figure Count:

2

Table Count:

0

Search Terms:

[15] Clinical neurology history, [16] Clinical neurology examination, [186] All Neuro-ophthalmology, [188] Optic nerve

Acknowledgment:**Study Funding:**

The authors report no targeted funding

Disclosures:

The authors report no relevant disclosures.

Preprint DOI:**Received Date:**

2022-07-04

Accepted Date:

2022-11-01

Handling Editor Statement:

Submitted and externally peer reviewed. The handling editor was Whitley Aamodt, MD, MPH.

Pearls:

- Optic atrophy in one eye and papilledema in the other is a tell-tale sign of Foster Kennedy syndrome and may be the presenting feature of an indolent slow-growing tumor.
- The finding of a Foster Kennedy syndrome should prompt expedited neuro-imaging.
- A junctional scotoma is a vision loss pattern consisting of ipsilateral central and contralateral supero-temporal field loss, suggestive of a lesion at the junction of the optic nerve and optic chiasm.
- Involvement of cranial nerves III, IV, VI, and the ophthalmic and maxillary branches of cranial nerve V may be indicative of a cavernous sinus localization.

Oy-sters:

- Pseudo-Foster Kennedy refers to optic atrophy in one eye and disc edema in the other caused by an etiology other than a compressive mass lesion, most commonly bilateral sequential non-arteritic ischemic optic neuropathy (NAION). Once a mass lesion has been ruled out, investigations should be done to evaluate alternative causes.
- Consider accompanying neurologic symptoms and signs outside of the neuro-ophthalmologic exam.

Unstructured Abstract:

Foster Kennedy syndrome refers to a finding of optic atrophy in one eye from direct compression of the optic nerve by a mass lesion and contralateral papilledema in the non-atrophic optic nerve caused by increased intracranial pressure. When the funduscopy finding is not due to a direct compressive mass, the term pseudo-Foster Kennedy syndrome is used; this can be caused by any process or processes that result in optic atrophy in one eye and optic disc edema in the other. Identifying Foster Kennedy syndrome in a patient calls for expedient neuroimaging looking for an intracranial mass lesion. In this paper, we present a case of a patient presenting with vision loss and Foster Kennedy syndrome who was found to have a large trigeminal cystic schwannoma. While several other accompanying symptoms were not evident from the patient complaint, careful history and physical examination revealed additional localizing clues: unilateral sensory changes in the face and pterygoid and masseter atrophy, unilateral cranial nerve VI palsy, and episodes of intense déjà vu sensation which were presumed to represent temporal lobe onset focal aware seizures. Trigeminal schwannomas are a rare entity, and they are even more rarely cystic. This case highlights an unusual scenario where slow expansion of the tumor ultimately resulted in vision loss and presentation of the patient to medical attention. To our knowledge, this is the first report of a trigeminal schwannoma causing Foster Kennedy syndrome.

A 28-year-old previously healthy man was seen at the neuro-ophthalmology clinic with a 5-month history of painless vision loss in the right eye. He reported gradual onset of a dark central scotoma which expanded over this period to include his entire field of vision. On further review of history, he described a four-year history of intermittent binocular horizontal diplopia that was worse in right gaze. He had also noticed episodes of intense déjà vu sensation followed by altered taste and smell and a rising epigastric sensation. These episodes would last 30 seconds, and awareness would be maintained throughout. He also noted longstanding numbness in his

right upper face which he had attributed to prior dental work. On neurological exam, his visual acuity was light perception in the right eye and 20/30 in the left eye. Humphrey automated perimetry demonstrated a pattern of dense central field loss in the right eye and a superior temporal field defect in the left eye (Figure 1). Color vision could not be assessed in the right eye and was normal in the left eye. There was a right relative afferent pupillary defect. Fundoscopy revealed optic disc pallor in the right eye and optic disc edema in the left eye (Figure 1). Optical coherence tomography (OCT) showed thinning of the right retinal nerve fiber layer (RNFL) with average thickness of 68 μ m with edema on the left with average RNFL thickness of 141 μ m. Efferent visual system examination showed esotropia in primary position which worsened on right gaze. There was a restriction in right eye abduction, consistent with a right cranial nerve VI palsy. Otherwise, saccades and smooth pursuit were normal, there was no ptosis, and the pupils were round, equal, and reactive to light. The remainder of the cranial nerve examination showed decreased sensation to light touch in the right face the distribution of all three trigeminal nerve branches and weakness and atrophy of the right pterygoid and masseter muscles.

An urgent enhanced CT head was arranged revealing a large extra-axial right frontal mass with significant mass effect and midline shift along with entrapment of the left lateral ventricle and effacement of the basal cisterns (Figure 2). There was adjacent bone remodeling, suggestive of a longstanding lesion. Further characterization of the lesion with enhanced MRI brain showed a large multi-cystic rim-enhancing extra-axial mass occupying much of the right middle cranial fossa, with extension to the right orbital apex and superior orbital fissure, foramen ovale, cavernous sinus, Meckel's cave, and right cerebellopontine angle cistern with accompanying compression of the pons and middle cerebellar peduncle. The patient was admitted to the neurosurgical service. An EEG was performed which showed moderate generalized background slowing, worse over the right hemisphere without any interictal epileptiform discharges, seizures, or any déjà vu events captured. However, the patient was started on phenytoin on clinical grounds. The lesion was resected in two stages. Histologically, it was predominantly comprised of Antoni A spindle cells in interlacing fascicles with a few regions of Antoni B architecture, as well as foci of hemosiderin deposition and degeneration. This was consistent with a WHO grade I schwannoma arising from the trigeminal nerve. Post-operatively, his right eye vision remained unchanged while his left eye visual acuity improved slightly to 20/25. He continued to have limitation of right eye abduction and occasional paresthesia involving the right hemiface. The episodes of déjà vu resolved.

Discussion

This case describes a patient presenting initially with subacute vision loss who was found to have a massive trigeminal cystic schwannoma. The clinical exam provided several neuro-anatomical localization clues which guided focused workup in the form of urgent neuroimaging and expedited neurosurgical consultation. The clinical picture of vision loss and optic disc pallor with papilledema on the contralateral side is consistent with Foster Kennedy syndrome, wherein a mass lesion directly compresses the ipsilateral optic nerve resulting in optic atrophy, while increased intracranial pressure from the mass results in papilledema in the contralateral, non-atrophied side¹. This eponymous syndrome was described by the prominent American neurologist Foster Kennedy. (Of note, he is well known to have held views in favor of eugenics, advocating for elimination or sterilization of impaired individuals². This historical perspective perhaps raises a case for renaming of the syndrome.) Foster Kennedy syndrome is classically

caused by olfactory groove, falx, sphenoidal wing, or subfrontal meningiomas¹. However, any compressive lesion can theoretically cause this presentation, and other reported etiologies include frontal abscesses, craniopharyngiomas, pituitary adenomas, plasmacytomas, neuroblastomas, nasopharyngeal angiofibromas, and aneurysms¹.

The pattern of visual field loss is in keeping with a junctional scotoma with a lesion at the junction of the optic nerve and chiasm compressing the ipsilateral optic nerve causing a central scotoma and affecting crossing fibers from the inferonasal retina of the contralateral eye resulting in a superotemporal scotoma in that eye (Figure 1). In contrast, a junctional scotoma of Traquair consists of a monocular nasal or temporal hemianopia and is also caused by a lesion at the junction of the optic nerve and chiasm, but only affecting nasal or temporal fibers. The most common cause for both visual field patterns is a pituitary adenoma; alternative causes include other compressive tumors (such as craniopharyngiomas, astrocytomas, or meningiomas)³.

The presence of ipsilateral cranial nerve VI palsy with involvement of the ophthalmic and maxillary branches of the trigeminal nerve is suggestive of a cavernous sinus localization. Cranial nerve VI and ophthalmic branch involvement (without the maxillary branch) could also invoke superior orbital fissure or orbital apex localization. However, there was also involvement of the mandibular branch, evidenced by lower face sensory changes and motor weakness and atrophy of the pterygoid and masseter muscles, most likely suggestive proximal trigeminal involvement. Finally, his recurrent episodes of intense déjà vu were felt to represent focal aware temporal lobe seizures, implying a lesion extending into the temporal region. Taken together, the constellation of findings is suggestive of a large compressive lesion affecting multiple cranial nerves, the optic chiasm, and the temporal lobe.

When the combination of optic atrophy and disc edema in the contralateral eye is caused by an etiology other than a compressive mass lesion, the term “pseudo-Foster Kennedy syndrome” is used. This can be seen in the setting of bilateral sequential non-arteritic anterior ischemic optic neuropathy (NAION)⁴⁻⁶ or optic neuritis⁴, but any event causing optic atrophy followed by an acute contralateral episode with disc edema can present similarly. Other reported causes include idiopathic intracranial hypertension⁷, syphilis⁴, traumatic optic neuropathy⁴, unilateral optic nerve hypoplasia with Chiari malformation⁸, p-ANCA positive pachymeningitis⁹, NAION with subsequent non-basal glioma¹⁰, gyrus rectus displacement by a distant tumor¹¹, and a meningioma infiltrating the superior sagittal sinus¹². There is one case report in the literature of what is termed “pseudo-pseudo-Foster Kennedy syndrome” where optic atrophy was caused by direct compression from a meningioma, while the contralateral nerve was swollen from concurrent NAION¹³.

The vestibulocochlear nerve is the most common location for intracranial schwannomas and trigeminal schwannomas are rare, accounting for less than 1% of intracranial tumors¹⁴. These masses tend to be solid neoplasms but cystic degeneration can rarely occur in approximately 7% of trigeminal schwannomas¹⁵. This may occur due to intra-tumoral bleeding, central ischemic, necrosis, or degenerative changes¹⁴. Management typically involves surgical resection although stereotactic radiosurgery can be employed for smaller lesions¹⁴.

In this case, we have described a patient presenting with vision loss and a constellation of findings that provided neuro-anatomical localizing clues: Foster Kennedy syndrome, cranial nerve VI palsy, motor and sensory trigeminal involvement, and suspected temporal lobe onset focal aware seizures. The neuro-ophthalmological exam finding of Foster Kennedy syndrome is important to recognize and should prompt neuro-imaging. To our knowledge, this is the first reported case of Foster Kennedy syndrome caused by a trigeminal schwannoma.

Figure 1. Fundus photos, perimetry, and diagram of junctional scotoma

A) Fundus photos showing optic disc pallor on the right and disc edema on the left; B) Visual fields using Humphrey automated perimetry showing dense depression on the right and a superotemporal defect on the left; C) Junctional scotoma schematic superimposed upon axial CT head image. The lesion causes optic nerve compression of the ipsilateral (right) eye (purple line) and dense visual field depression. Additionally, there is compression of the inferonasal retinal fibers from the contralateral (left) eye (red line) resulting in a supero-temporal defect. This pattern of vision loss is known as a junctional scotoma and is suggestive of a lesion at the junction of the optic nerve and chiasm.

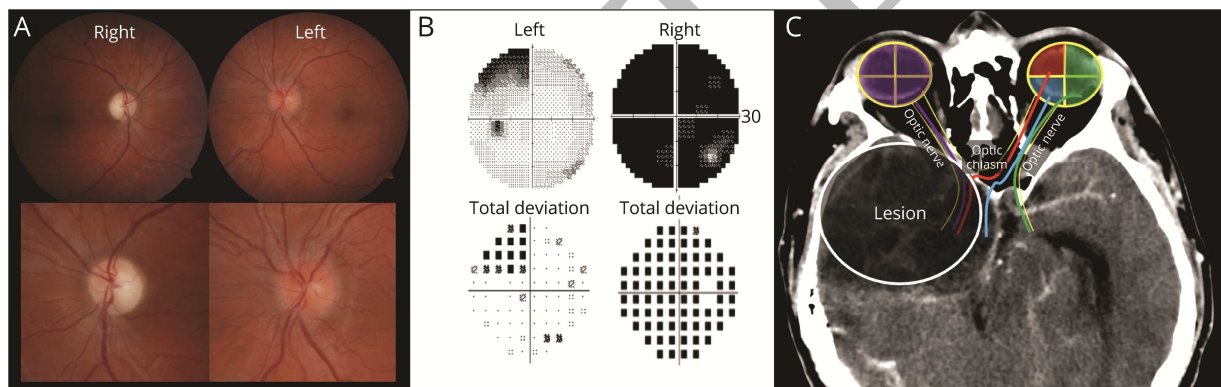
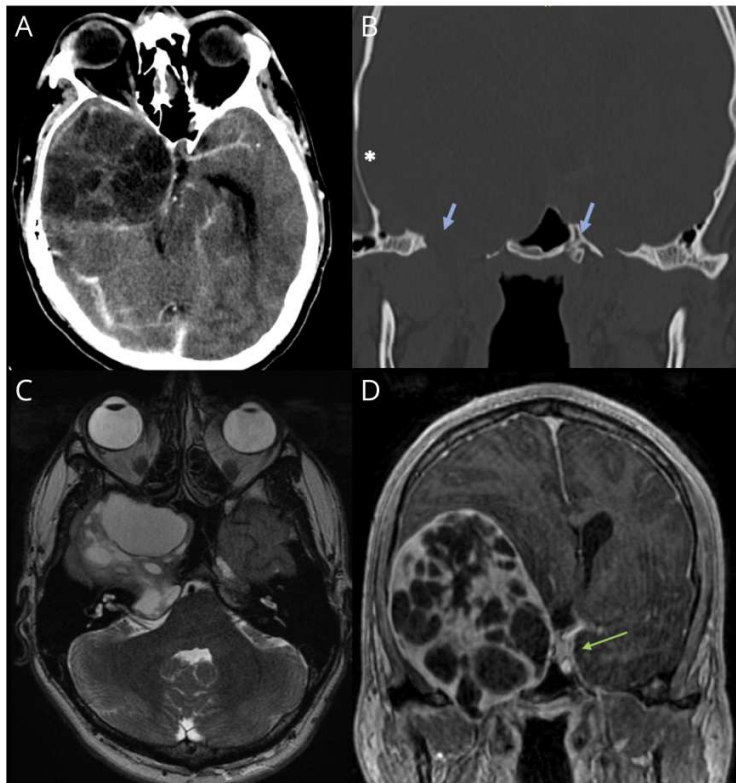


Figure 2. CT and MRI imaging showing a large cystic tumor

CT head with contrast (A) showing a large heterogenous right middle cranial fossa lesion with mass effect; bone window (B) showing thinning and remodeling on the right adjacent skull (asterisk) with the foramen ovale on both sides are marked (blue arrows), demonstrating expansion on the right through which the mass extends. Axial T2 MR (C) shows a heterogenous dumbbell-shaped multilobulated mass. Coronal T1 post contrast MR (D) shows a cystic ring-enhancing mass; the green arrow marks the cavernous sinus on the unaffected left side demonstrating extension of the mass into cavernous sinus on the right side.



References

1. Lotfipour S, Chiles K, Kahn JA, Bey T, Rudkin S. An unusual presentation of subfrontal meningioma: A case report and literature review for Foster Kennedy syndrome. *Intern Emerg Med*. 2011;6(3):267-269. doi:10.1007/S11739-010-0437-Y
2. Offen ML. Dealing with “defectives” Foster Kennedy and William Lennox on eugenics. *Neurology*. 2003;61(5):668-673. doi:10.1212/WNL.61.5.668
3. Schiefer U, Isbert M, Mikolaschek E, et al. Distribution of scotoma pattern related to chiasmal lesions with special reference to anterior junction syndrome. *Graefes Arch Clin Exp Ophthalmol*. 2004;42(6):468-477. doi:10.1007/S00417-004-0863-5
4. Schatz NJ, Smith JL. Non-Tumor Causes of the Foster Kennedy Syndrome. *J Neurosurg*. 1967;27(1):37-44. doi:10.3171/JNS.1967.27.1.0037
5. Patil A, Takkar A, Goyal M, Singh R, Lal V. Sequential NAION presenting as pseudo Foster Kennedy syndrome. *J Neurol Sci*. 2017;376:49-51. doi:10.1016/J.JNS.2017.02.002
6. Lepore FE, Yarian DL. A mimic of the “exact diagnostic sign” of Foster Kennedy. *Ann Ophthalmol*. 1985;17(7):411-412.
7. Micieli JA, Al-Obthani M, Sundaram ANE. Pseudo-Foster Kennedy syndrome due to idiopathic intracranial hypertension. *Can J Ophthalmol*. 2014;49(4):e99-e102. doi:10.1016/J.JCJO.2014.05.002
8. Bansal S, Dabbs T, Long V. Pseudo-Foster Kennedy Syndrome due to unilateral optic nerve hypoplasia: a case report. *J Med Case Rep*. 2008;2:86. doi:10.1186/1752-1947-2-86
9. Tamai H, Tamai K, Yuasa H. Pachymeningitis with pseudo-Foster Kennedy syndrome. *Am J Ophthalmol*. 2000;130(4):535-537. doi:10.1016/S0002-9394(00)00566-3
10. Limaye SR, Adler J. Pseudo-Foster Kennedy syndrome in a patient with anterior ischemic optic neuropathy and a nonbasal glioma. *J Clin Neuroophthalmol*. 1990;10(3):188-192.
11. Desai N, Yong RL, Doshi A, Rucker JC. Pseudo-Foster-Kennedy syndrome with optic nerve compression by the gyrus rectus. *Neurology*. 2015;85(4):385-385. doi:10.1212/WNL.0000000000001791
12. Semeraro F, Forbice E, Duse S, Costagliola C. Pseudo-Foster Kennedy syndrome in a young woman with meningioma infiltrating the superior sagittal sinus. *Clin Neurol Neurosurg*. 2012;114(3):272-274. doi:10.1016/J.CLINNEURO.2011.10.018
13. Gelwan MJ, Seidman M, Kupersmith MJ. Pseudo-pseudo-Foster Kennedy syndrome. *J Clin Neuroophthalmol*. 1988;8(1):49-52.
14. Ortega-Merchan MP, Reyes F, Mejía JA, Rivera DM, Galvis JC, Marquez JC. Cystic trigeminal schwannomas. *Radiol Case Reports*. 2019;14(12):1513. doi:10.1016/J.RADCR.2019.09.031
15. Wanibuchi M, Fukushima T, Zomordi AR, Nonaka Y, Friedman AH. Trigeminal schwannomas: skull base approaches and operative results in 105 patients. *Neurosurgery*. 2012;70(1 Suppl Operative). doi:10.1227/NEU.0B013E31822E3B21

Neurology®

Pearls & Oy-sters: Trigeminal Cystic Schwannoma Presenting With Foster Kennedy Syndrome, Sixth Nerve Palsy, and Focal Seizures

Yasamin Mahjoub, Miranda Wan and Suresh Subramaniam

Neurology published online December 19, 2022

DOI 10.1212/WNL.0000000000201700

This information is current as of December 19, 2022

Updated Information & Services	including high resolution figures, can be found at: http://n.neurology.org/content/early/2022/12/19/WNL.0000000000201700.full
Subspecialty Collections	This article, along with others on similar topics, appears in the following collection(s): All Neuro-ophthalmology http://n.neurology.org/cgi/collection/all_neuroophthalmology Clinical neurology examination http://n.neurology.org/cgi/collection/clinical_neurology_examination Clinical neurology history http://n.neurology.org/cgi/collection/clinical_neurology_history Optic nerve http://n.neurology.org/cgi/collection/optic_nerve
Permissions & Licensing	Information about reproducing this article in parts (figures, tables) or in its entirety can be found online at: http://www.neurology.org/about/about_the_journal#permissions
Reprints	Information about ordering reprints can be found online: http://n.neurology.org/subscribers/advertise

Neurology® is the official journal of the American Academy of Neurology. Published continuously since 1951, it is now a weekly with 48 issues per year. Copyright © 2022 American Academy of Neurology. All rights reserved. Print ISSN: 0028-3878. Online ISSN: 1526-632X.

