

Teaching NeuroImage: Radial Compression Neuropathy Secondary to Accessory Belly of the Triceps Muscle

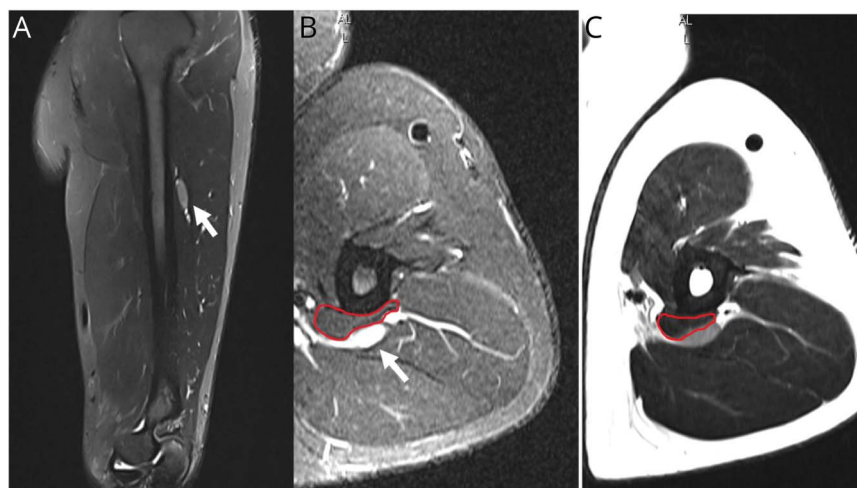
Pablo Bastias, MD,* Romulo Melo, MD, Jose Manuel Matamala, MD, PhD, Nicholas Earle, MD, and Ignacio Acosta, MD*

Neurology® 2023;101:e984-e985. doi:10.1212/WNL.0000000000207394

Correspondence

Dr. Acosta
ignacioacosta@uchile.cl

Figure 1 Left Arm MRI Without Contrast



(A) Sagittal STIR, (B) axial STIR, and (C) axial T2 images. The radial nerve (white arrows) has focal thickening and increased signal at the level of the middle third of the humerus. An accessory muscle belly of the triceps (red lines; B, C) is visualized compressing the radial nerve. STIR = short tau inversion recovery.

A 43-year-old man presented with 5 months of left hand pain, extensor weakness, and dorsal sensory loss. There was no history of trauma, infection, or exercise-related symptoms. Neurologic examination showed atrophy and weakness (4/5 on the Medical Research Council scale) of the left brachioradialis, wrist, and finger extensor muscles. Sensation to pinprick and touch was reduced over the dorsum of the left hand. Nerve conduction velocity showed a reduction in compound muscle action potential (1.0 mV) and sensory nerve action potential (14 μ V) amplitudes in the left radial nerve. No conduction blocks or focal slowing were recorded. EMG also showed active denervation of the brachioradialis and forearm extensor muscles, sparing the triceps. An axonal radial sensorimotor neuropathy proximal to the brachioradialis muscle was diagnosed. Left arm MRI, ultrasound, and surgical exploration showed an entrapment of the radial nerve in the upper arm due to a triceps accessory muscle belly (Figures 1 and 2). Muscle anatomical variants are an infrequent cause of radial nerve entrapment, and images are crucial to identify this etiology.^{1,2}

MORE ONLINE

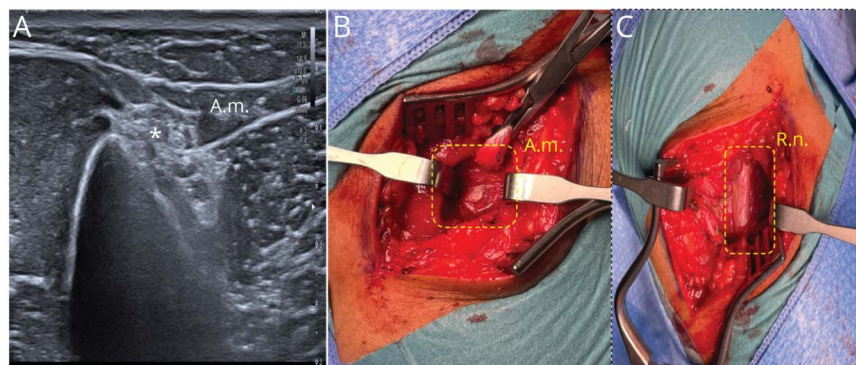
Teaching slides

links.lww.com/WNL/C800

*These authors contributed equally to this work.

From the Neurology and Translational Neurophysiology Laboratory (NODO Lab) (P.B., J.M.M., I.A.), University of Chile, Medicine Faculty; Hospital Clínico de la Fuerza Aérea de Chile (FACH) (P.B.), General Dr. Raúl Yazigi J.; Neurology and Psychiatry Department (J.M.M, I.A.), Clínica Alemana de Santiago de Chile; Departamento Cirugía (R.M), Clínica Alemana, Santiago, Chile; Departamento de Ciencias Neurológicas Oriente (R.M., J.M.M., I.A.), University of Chile; Instituto Milenio de Neurociencia Biomedica (BNI) (J.M.M.), University of Chile; Servicio de Neurocirugía, Instituto de Neurocirugía Dr. Asenjo (R.M); Neurology and Neurosurgery Department (N.E.), Clínica Davila; and Neurology Department (I.A.), Hospital del Salvador, Santiago, Chile.

Go to Neurology.org/N for full disclosures. Funding information and disclosures deemed relevant by the authors, if any, are provided at the end of the article.



Left radial nerve (R.n.) ultrasound (A). The R.n. (asterisk) has increased echogenicity and cross-sectional area at the middle third of the humerus; the accessory belly of the triceps muscle (A.m.) is shown. Surgical decompression pre-R.n. release (B) and post-R.n. release (C) confirmed this entrapment etiology.

Author Contributions

P. Bastias: drafting/revision of the manuscript for content, including medical writing for content; major role in the acquisition of data; study concept or design; analysis or interpretation of data. R. Melo: drafting/revision of the manuscript for content, including medical writing for content; analysis or interpretation of data. J.M. Matamala: drafting/revision of the manuscript for content, including medical writing for content; analysis or interpretation of data. N. Earle: drafting/revision of the manuscript for content, including medical writing for content; analysis or interpretation of data. I. Acosta: drafting/revision of the manuscript for content, including medical writing for content; major role in the acquisition of data; study concept or design; analysis or interpretation of data.

Study Funding

No targeted funding reported.

Disclosure

The authors report no relevant disclosures. Go to [Neurology.org/N](https://www.neurology.org/N) for full disclosures.

Publication History

Received by *Neurology* October 4, 2022. Accepted in final form March 23, 2023. Submitted and externally peer reviewed. The handling editor was Resident & Fellow Section Editor Whitley Aamodt, MD, MPH.

References

1. Agarwal A, Chandra A, Jaipal U, Saini N. A panorama of radial nerve pathologies: an imaging diagnosis: a step ahead. *Insights Imaging*. 2018;9(6):1021-1034. doi:10.1007/s13244-018-0662-x
2. Tubbs RS, Salter EG, Oakes WJ. Triceps brachii muscle demonstrating a fourth head. *Clin Anat*. 2006;19(7):657-660. doi:10.1002/ca.20326

Neurology®

Teaching NeuroImage: Radial Compression Neuropathy Secondary to Accessory Belly of the Triceps Muscle

Pablo Bastias, Romulo Melo, Jose Manuel Matamala, et al.
Neurology 2023;101:e984-e985 Published Online before print May 8, 2023
DOI 10.1212/WNL.0000000000207394

This information is current as of May 8, 2023

Updated Information & Services	including high resolution figures, can be found at: http://n.neurology.org/content/101/9/e984.full
References	This article cites 2 articles, 0 of which you can access for free at: http://n.neurology.org/content/101/9/e984.full#ref-list-1
Subspecialty Collections	This article, along with others on similar topics, appears in the following collection(s): EMG http://n.neurology.org/cgi/collection/emg Peripheral neuropathy http://n.neurology.org/cgi/collection/peripheral_neuropathy Ultrasound http://n.neurology.org/cgi/collection/ultrasound
Permissions & Licensing	Information about reproducing this article in parts (figures, tables) or in its entirety can be found online at: http://www.neurology.org/about/about_the_journal#permissions
Reprints	Information about ordering reprints can be found online: http://n.neurology.org/subscribers/advertise

Neurology® is the official journal of the American Academy of Neurology. Published continuously since 1951, it is now a weekly with 48 issues per year. Copyright © 2023 American Academy of Neurology. All rights reserved. Print ISSN: 0028-3878. Online ISSN: 1526-632X.

