

Teaching NeuroImage: Etiologic Investigation Using Optical Coherence Tomography During Thrombectomy

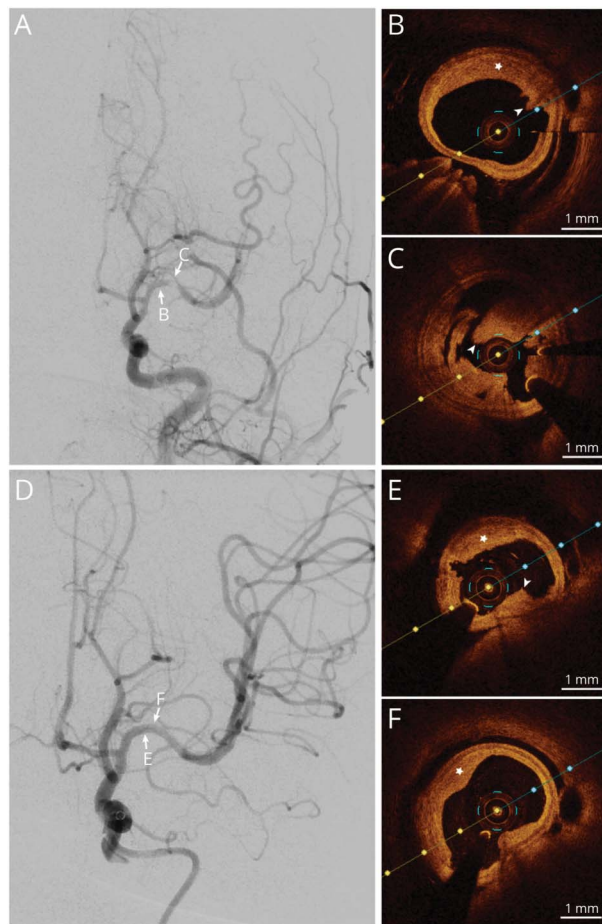
Di Li, MD, PhD,* Tao Tang, MD,* Teng Hu, MD,* Chun-Yu Yu, BS, Aline M. Thomas, PhD, Man-Hong Zhao, MD, Tie-Ping Fan, MD, and Shen Li, MD, PhD

Neurology® 2023;101:280-281. doi:10.1212/WNL.0000000000207345

Correspondence

Dr. Li
lishen@mail.ccmu.edu.cn

Figure Intraoperative Findings



(A) A filling defect after the first clot retrieval. (B and C) OCT revealed a fibrous plaque with intact fibrous cap (low-attenuating, signal-rich lesion, star) and white thrombi (intraluminal low-attenuating, signal-rich masses, arrow-head). (D) A successful second clot retrieval. (E and F) Repeated OCT confirmed the unruptured plaque and residual white thrombi. OCT = optical coherence tomography.

MORE ONLINE

Teaching slides

links.lww.com/WNL/C793

A 24-year-old man with an acute left middle cerebral artery occlusion underwent a thrombectomy. A filling defect was observed in the culprit lesion after the first clot retrieval (Figure, A). Intraoperative optical coherence tomography (OCT) was then performed to investigate the etiology,

*These authors contributed equally to this work.

From the Department of Neurointervention (D.L., T.H., C.-Y.Y., M.-H.Z., T.-P.F.), Dalian Municipal Central Hospital affiliated with Dalian Medical University; Department of Neurology and Psychiatry (T.T., S.L.), Beijing Shijitan Hospital, Capital Medical University, China; The Russell H. Morgan Department of Radiology and Radiological Sciences (A.M.T.), the Johns Hopkins University School of Medicine, Baltimore, MD; and Beijing Institute of Brain Disorders (S.L.), Capital Medical University, China.

Go to Neurology.org/N for full disclosures. Funding information and disclosures deemed relevant by the authors, if any, are provided at the end of the article.

which revealed a fibrous plaque with an intact fibrous cap and intraluminal white thrombi (Figure, B and C). Complete reperfusion was achieved with a second clot retrieval (Figure, D). Repeated OCT confirmed recanalization and the absence of ruptured plaque (Figure, E and F), indicating large artery atherosclerosis with plaque erosion caused the in situ thrombosis.¹ Adjunctive antiplatelet therapy was administered, and functional independence was achieved at 90 days. OCT provides insight on intrinsic vessel wall disease with high spatial resolution.² It can act as a robust tool for ambiguous etiologic diagnosis during thrombectomy, shedding light on personalized adjunctive treatment and proper secondary prevention strategy to improve outcome.

Standard Protocol Approvals and Patient Consents

The study was approved by the Ethical Committee of Dalian Municipal Central Hospital affiliated with Dalian Medical University (approval number 2022-035-01). A written consent-to-disclose form from the patient was obtained.

Author Contributions

D. Li: drafting/revision of the manuscript for content, including medical writing for content; major role in the acquisition of data; study concept or design; analysis or interpretation of data. T. Tang: drafting/revision of the manuscript for content, including medical writing for content; major role in the acquisition of data; study concept or design; analysis or interpretation of data. T. Hu: drafting/revision of the manuscript for content, including medical writing for content; major role in the acquisition of data; study concept or design; analysis or interpretation

of data. C.-Y. Yu: major role in the acquisition of data; analysis or interpretation of data. A.M. Thomas: drafting/revision of the manuscript for content, including medical writing for content. M.-H. Zhao: major role in the acquisition of data; study concept or design; analysis or interpretation of data. T.-P. Fan: drafting/revision of the manuscript for content, including medical writing for content; major role in the acquisition of data; study concept or design; analysis or interpretation of data. S. Li: drafting/revision of the manuscript for content, including medical writing for content; major role in the acquisition of data; study concept or design; analysis or interpretation of data.

Study Funding

This work was supported by National Natural Science Foundation of China (82171319), Beijing Municipal Science & Technology Commission (Z221100007422111), and Central Committee Healthcare Project (2020YB64).

Disclosure

All authors report no disclosures relevant to the manuscript. Go to [Neurology.org/N](https://www.neurology.org/N) for full disclosures.

Publication History

Received by *Neurology* November 8, 2022. Accepted in final form March 10, 2023. Submitted and externally peer reviewed. The handling editor was Resident & Fellow Section Editor Whitley Aamodt, MD, MPH.

References

1. Araki M, Park SJ, Dauerman HL, et al. Optical coherence tomography in coronary atherosclerosis assessment and intervention. *Nat Rev Cardiol*. 2022;19(10):684-703.
2. Li D, Tang T, Hu T, Walczak P, Gandhi D, Li S. Application of optical coherence tomography in decision-making of post-thrombectomy adjunctive treatments. *J Neurointerv Surg*. 2023;15(6):616-618. doi:10.1136/jnis-2022-019195

Disputes & Debates: Rapid Online Correspondence

The editors encourage comments on recent articles through Disputes & Debates:

Access an article at [Neurology.org/N](https://www.neurology.org/N) and click on “MAKE COMMENT” beneath the article header.

Before submitting a comment to Disputes & Debates, remember the following:

- Disputes & Debates is restricted to comments about articles published in *Neurology* within 6 months of issue date, but the editors will consider a longer time period for submission if they consider the letter a significant addition to the literature
- Read previously posted comments; redundant comments will not be posted
- Your submission must be 200 words or less and have a maximum of 5 references; the first reference must be the article on which you are commenting
- You can include a maximum of 5 authors (including yourself)

Neurology[®]

Teaching NeuroImage: Etiologic Investigation Using Optical Coherence Tomography During Thrombectomy

Di Li, Tao Tang, Teng Hu, et al.

Neurology 2023;101;280-281 Published Online before print May 2, 2023

DOI 10.1212/WNL.0000000000207345

This information is current as of May 2, 2023

Updated Information & Services	including high resolution figures, can be found at: http://n.neurology.org/content/101/6/280.full
References	This article cites 2 articles, 1 of which you can access for free at: http://n.neurology.org/content/101/6/280.full#ref-list-1
Subspecialty Collections	This article, along with others on similar topics, appears in the following collection(s): All Cerebrovascular disease/Stroke http://n.neurology.org/cgi/collection/all_cerebrovascular_disease_stroke All Imaging http://n.neurology.org/cgi/collection/all_imaging Infarction http://n.neurology.org/cgi/collection/infarction Prognosis http://n.neurology.org/cgi/collection/prognosis Stroke in young adults http://n.neurology.org/cgi/collection/stroke_in_young_adults
Permissions & Licensing	Information about reproducing this article in parts (figures, tables) or in its entirety can be found online at: http://www.neurology.org/about/about_the_journal#permissions
Reprints	Information about ordering reprints can be found online: http://n.neurology.org/subscribers/advertise

Neurology® is the official journal of the American Academy of Neurology. Published continuously since 1951, it is now a weekly with 48 issues per year. Copyright © 2023 American Academy of Neurology. All rights reserved. Print ISSN: 0028-3878. Online ISSN: 1526-632X.

