

Teaching Video NeuroImage: Delayed Radiation-Induced Unilateral Myokymia of the Tongue

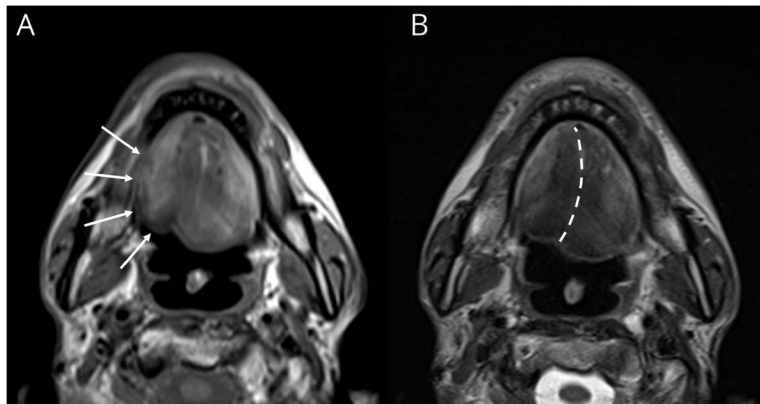
Gianmaria Senerchia, MD, Valentina Virginia Iuzzolino, MD, Stefano Zoccolella, MD, Lorenzo Ugga, MD, PhD, Rosa Iodice, MD, Fiore Manganelli, MD, and Raffaele Dubbioso, MD, PhD

Neurology® 2023;100:351-352. doi:10.1212/WNL.0000000000201607

Correspondence

Dr. Dubbioso
rafdubbioso@gmail.com

Figure MRI of the Tongue



Axial T1-weighted (A) and T2-weighted (B) images showing prominent right hemitongue atrophy (arrows). The dotted line indicates the course of the lingual septum.

A 49-year-old man with undifferentiated nasopharyngeal carcinoma underwent 2 cycles of chemotherapy, followed by right-side head and neck radiation therapy. Thirteen years later, he developed progressive dysphagia and dysarthria. Neurologic examination showed atrophy associated with wave-like movements and prominent rippling in the right side of the tongue; needle electromyography revealed myokymic discharges in the right genioglossus muscle (Video 1). MRI of the head and neck confirmed isolated unilateral tongue atrophy (Figure) while laryngoscopy showed delayed initiation of swallowing and reduced laryngeal elevation.

Delayed effects of radiation therapy could be seen even decades later and are directly related to radiation dosage.¹ Myokymic discharges of the tongue are likely due to the damage of the hypoglossal nerve induced by microvascular injury and fibrosis with subsequent hyperexcitability of the axon membrane.¹ In an oncology patient, myokymia is usually associated with radiation-induced neuropathy rather than cancer recurrence.²

Study Funding

No targeted funding reported.

Disclosure

The authors report no relevant disclosures. Go to [Neurology.org/N](https://www.neurology.org/N) for full disclosures.

Publication History

Received by *Neurology* July 22, 2022. Accepted in final form October 11, 2022. Submitted and externally peer reviewed. The handling editor was Whitley Aamodt, MD, MPH.

From the Department of Neurosciences (G.S., V.I., R.I., F.M., R.D.), Reproductive Sciences and Odontostomatology, University Federico II of Naples; Clinical Neurophysiology Unit (S.Z.), San Paolo Hospital, Bari; and Department of Advanced Biomedical Sciences (L.U.), University Federico II of Naples, Italy.

Go to [Neurology.org/N](https://www.neurology.org/N) for full disclosures.

MORE ONLINE

 Video

Teaching slides

links.lww.com/WNL/C499

Appendix Authors

Name	Location	Contribution
Gianmaria Senerchia, MD	Department of Neurosciences, Reproductive Sciences and Odontostomatology, University Federico II of Naples, Italy	Drafting/revision of the manuscript for content, including medical writing for content; major role in the acquisition of data
Valentina Virginia Iuzzolino, MD	Department of Neurosciences, Reproductive Sciences and Odontostomatology, University Federico II of Naples, Italy	Study concept or design; analysis or interpretation of data
Stefano Zoccolella, MD	Clinical Neurophysiology Unit, San Paolo Hospital, Bari, Italy	Study concept or design; analysis or interpretation of data
Lorenzo Uggia, MD, PhD	Department of Advanced Biomedical Sciences, University Federico II of Naples, Italy	Major role in the acquisition of data; analysis or interpretation of data
Rosa Iodice, MD	Department of Neurosciences, Reproductive Sciences and Odontostomatology, University Federico II of Naples, Italy	Study concept or design; analysis or interpretation of data

Appendix (continued)

Name	Location	Contribution
Fiore Manganelli, MD	Department of Neurosciences, Reproductive Sciences and Odontostomatology, University Federico II of Naples, Italy	Study concept or design; analysis or interpretation of data
Raffaele Dubbioso, MD, PhD	Department of Neurosciences, Reproductive Sciences and Odontostomatology, University Federico II of Naples, Italy	Drafting/revision of the manuscript for content, including medical writing for content; major role in the acquisition of data; study concept or design; analysis or interpretation of data

References

1. Delanian S, Lefaix JL, Pradat PF. Radiation-induced neuropathy in cancer survivors. *Radiother Oncol.* 2012;105(3):273-282. doi:10.1016/j.radonc.2012.10.012.
2. Tiftikcioglu BI, Bulbul I, Ozcelik MM, Piskin-Demir G, Zorlu Y. Tongue myokymia presenting twelve years after radiation therapy. *Clin Neurophysiol Pract.* 2016;1:41-42. doi:10.1016/j.cnp.2016.05.002.

Announcing...

Child Neurology: A Case-Based Approach Cases From the Neurology® Resident & Fellow Section

This collaboration between the American Academy of Neurology (AAN) and the Child Neurology Society (CNS) represents a collection of reprinted cases from the past 15 years from the Neurology Resident & Fellow Section.

An invaluable resource for both adult and pediatric neurologists and trainees! FREE download: [NPub.org/cnbook](https://www.ncbi.nlm.nih.gov/pmc/books/ncnbook/)

Call for Voices: Lived Experiences

The Editor of the *Neurology* specialty section Inclusion, Diversity, Equity, Anti-racism, & Social Justice (IDEAS) encourages you to submit short first-person accounts (1,000 words or less) of experiences lived within the realm of IDEAS with the goal of informing and enlightening our community on these critical issues. Some topics to consider include, but are not limited to:

- Descriptions of personal experiences that shaped your views of IDEAS.
- Reflections on the intersection between personal identity and career.
- Discussions at the intersection of IDEAS and neurology patient care, research, education, advocacy, or policy.

Submit your contributions to journal@neurology.org and include "Voices Submission" in the subject line.

Neurology[®]

Teaching Video NeuroImage: Delayed Radiation-Induced Unilateral Myokymia of the Tongue

Gianmaria Senerchia, Valentina Virginia Iuzzolino, Stefano Zoccolella, et al.
Neurology 2023;100;351-352 Published Online before print November 29, 2022
DOI 10.1212/WNL.0000000000201607

This information is current as of November 29, 2022

Updated Information & Services	including high resolution figures, can be found at: http://n.neurology.org/content/100/7/351.full
References	This article cites 2 articles, 0 of which you can access for free at: http://n.neurology.org/content/100/7/351.full#ref-list-1
Subspecialty Collections	This article, along with others on similar topics, appears in the following collection(s): All Movement Disorders http://n.neurology.org/cgi/collection/all_movement_disorders EMG http://n.neurology.org/cgi/collection/emg Radiation therapy-tumor http://n.neurology.org/cgi/collection/radiation_therapytumor
Permissions & Licensing	Information about reproducing this article in parts (figures, tables) or in its entirety can be found online at: http://www.neurology.org/about/about_the_journal#permissions
Reprints	Information about ordering reprints can be found online: http://n.neurology.org/subscribers/advertise

Neurology® is the official journal of the American Academy of Neurology. Published continuously since 1951, it is now a weekly with 48 issues per year. Copyright © 2022 American Academy of Neurology. All rights reserved. Print ISSN: 0028-3878. Online ISSN: 1526-632X.

