

Teaching NeuroImage: Mobile Hypopyon as a Clinical Clue for the Diagnosis of Behçet Disease

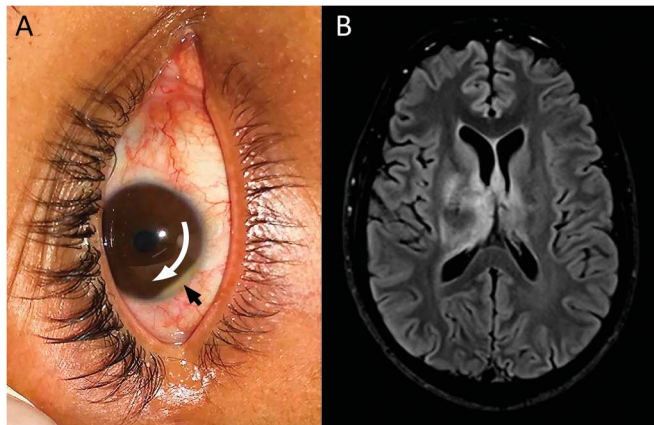
Igor Melo de Almeida, MD, Flavio Moura Rezende Filho, MD, PhD, José Luiz Pedrosa, MD, PhD, and Orlando Barsottini, MD, PhD

Neurology® 2023;100:307-308. doi:10.1212/WNL.0000000000201577

Correspondence

Dr. Rezende Filho
flaviomourarezende@
hotmail.com

Figure Ocular Findings and Neuroimaging



External eye photograph depicts the mobile hypopyon (black arrow) and its movement within the anterior chamber right after the patient changed the position from standing to right lateral decubitus (curved arrow) (A). Brain MRI axial FLAIR-weighted image shows confluent hyperintense lesions in the diencephalon (B).

A 29-year-old man presented with subacute new-onset headache, confusion, and hallucinations. On examination, he had obtundation and bilateral decreased visual acuity. Brain MRI revealed a T2/fluid-attenuated inversion recovery (FLAIR) hyperintense signal of the diencephalon and basal ganglia. Subsequently, he developed anterior uveitis with mobile hypopyon (Figure). Further questioning of his wife disclosed previous episodes of “red eyes,” acne-like skin lesions, and oral ulcers.

He was diagnosed with Behçet disease (BD) and fully recovered after a methylprednisolone pulse. The hallmarks of BD are oral and genital ulcers and uveitis. Neuro-BD often presents with cerebral venous thrombosis, aseptic meningitis, or mesodiencephalic venulitis. Although confluent diencephalic lesions on neuroimaging strongly indicate Neuro-BD, the diagnosis also relies on clinical findings.¹ Hypopyon is the sedimentation of leukocytes in the anterior chamber of the eye, which manifests as a whitish fluid level. Mobile hypopyon is typical of NB and a relevant diagnostic clue.²

Study Funding

The authors report no targeted funding.

Disclosure

The authors report no relevant disclosures. Go to [Neurology.org/N](https://www.neurology.org/N) for full disclosures.

MORE ONLINE

Teaching slides

links.lww.com/WNL/C476

From the Division of General Neurology and Ataxia Unit, Department of Neurology, Universidade Federal de São Paulo, São Paulo, SP, Brazil.

Go to [Neurology.org/N](https://www.neurology.org/N) for full disclosures.

Publication History

Received by *Neurology* July 4, 2022. Accepted in final form October 6, 2022. Submitted and externally peer reviewed. The handling editor was Whitley Aamodt, MD, MPH.

Appendix Authors

Name	Location	Contribution
Igor Melo de Almeida, MD	Division of General Neurology and Ataxia Unit, Department of Neurology, Universidade Federal de São Paulo, São Paulo, SP, Brazil	Drafting/revision of the manuscript for content, including medical writing for content; major role in the acquisition of data; study concept or design; analysis or interpretation of data
Flavio Moura Rezende Filho, MD, PhD	Division of General Neurology and Ataxia Unit, Department of Neurology, Universidade Federal de São Paulo, São Paulo, SP, Brazil	Drafting/revision of the manuscript for content, including medical writing for content; major role in the acquisition of data; study concept or design; analysis or interpretation of data

Appendix (continued)

Name	Location	Contribution
José Luiz Pedroso, MD, PhD	Division of General Neurology and Ataxia Unit, Department of Neurology, Universidade Federal de São Paulo, São Paulo, SP, Brazil	Drafting/revision of the manuscript for content, including medical writing for content; major role in the acquisition of data; study concept or design; analysis or interpretation of data
Orlando Barsottini, MD, PhD	Division of General Neurology and Ataxia Unit, Department of Neurology, Universidade Federal de São Paulo, São Paulo, SP, Brazil	Drafting/revision of the manuscript for content, including medical writing for content; major role in the acquisition of data; study concept or design; analysis or interpretation of data

References

1. Kalra S, Silman A, Akman-Demir G, et al. Diagnosis and management of Neuro-Behçet's disease: international consensus recommendations. *J Neurol*. 2014;261(9):1662-1676.
2. Zalka FR, Chang PY, Giuliari GP, Foster CS. Current trends in the management of ocular symptoms in Adamantiades-Beçet's disease. *Clin Ophthalmol*. 2009;3:567-579. doi:10.2147/oph.s4445".

Announcing...


Child Neurology: A Case-Based Approach Cases From the Neurology® Resident & Fellow Section


This collaboration between the American Academy of Neurology (AAN) and the Child Neurology Society (CNS) represents a collection of reprinted cases from the past 15 years from the Neurology Resident & Fellow Section.

An invaluable resource for both adult and pediatric neurologists and trainees! FREE download: NPub.org/cnbook

Visit the Neurology® Website at Neurology.org/N

- More article-based content on home pages
- Streamlined menus and navigation
- Enhanced blog sections for specialty areas
- Same experience on desktop, tablet, and mobile devices
- Improved article reading experience; links more evident (pdf, analytics, social media)

 Find *Neurology*® on Facebook: <http://tinyurl.com/neurologyfan>

 Follow *Neurology*® on Twitter: <https://twitter.com/GreenJournal>

Neurology®

Teaching NeuroImage: Mobile Hypopyon as a Clinical Clue for the Diagnosis of Behçet Disease

Igor Melo de Almeida, Flavio Moura Rezende Filho, José Luiz Pedroso, et al.
Neurology 2023;100;307-308 Published Online before print November 10, 2022
DOI 10.1212/WNL.0000000000201577

This information is current as of November 10, 2022

Updated Information & Services	including high resolution figures, can be found at: http://n.neurology.org/content/100/6/307.full
References	This article cites 2 articles, 0 of which you can access for free at: http://n.neurology.org/content/100/6/307.full#ref-list-1
Subspecialty Collections	This article, along with others on similar topics, appears in the following collection(s): All Neuro-ophthalmology http://n.neurology.org/cgi/collection/all_neuroophthalmology Autoimmune diseases http://n.neurology.org/cgi/collection/autoimmune_diseases Clinical neurology examination http://n.neurology.org/cgi/collection/clinical_neurology_examination Vasculitis http://n.neurology.org/cgi/collection/vasculitis
Permissions & Licensing	Information about reproducing this article in parts (figures, tables) or in its entirety can be found online at: http://www.neurology.org/about/about_the_journal#permissions
Reprints	Information about ordering reprints can be found online: http://n.neurology.org/subscribers/advertise

Neurology® is the official journal of the American Academy of Neurology. Published continuously since 1951, it is now a weekly with 48 issues per year. Copyright © 2022 American Academy of Neurology. All rights reserved. Print ISSN: 0028-3878. Online ISSN: 1526-632X.

