

Clinical Reasoning: A Young Adult Man With Cognitive Changes, Gait Difficulty, and Renal Insufficiency

Brian Stamm, MD, Rebecca DiBiase, MD, MPH, Glenn Ryan Harris, MD, Hagop Kaprielian, MD, Nupur Brahmabhatt, MD, Allan D. Wu, MD, Joshua Baker, DO,* and Eric M. Liotta, MD, MS*

Neurology® 2023;100:206-212. doi:10.1212/WNL.0000000000201500

Correspondence

Dr. Stamm
brian.stamm@
northwestern.edu

Abstract

A 22-year-old right-handed man with recently diagnosed gout and renal insufficiency presented with 3 months of progressive gait instability and cognitive changes. He initially presented to an outside institution and underwent a broad workup, but an etiology for his symptoms was not found. On subsequent presentation to our institution, his examination revealed multidomain cognitive dysfunction, spasticity, hyperreflexia, and clonus. A broad workup was again pursued and was notable for an MRI of the brain, revealing cortical atrophy advanced for his age, bland CSF, and a weakly positive serum acetylcholine receptor ganglionic neuronal antibody of unclear significance. The history of gout and inadequately explained renal insufficiency led to a workup for inborn errors of metabolism, including urine amino acid analysis, which revealed a homocysteine peak. This finding prompted further evaluation, revealing markedly elevated serum homocysteine and methylmalonic acid and low methionine. He ultimately developed superficial venous thromboses, a segmental pulmonary embolism, and clinical and electrographic seizures. He was initiated on appropriate treatment, and his symptoms markedly improved. The case serves as a reminder to include late-onset inborn errors of metabolism in the differential for young adult patients with onset of neurologic, psychiatric, renal, and thromboembolic symptoms.

*These authors contributed equally to this work as senior authors.

From the Ken & Ruth Davee Department of Neurology (B.S., R.D., G.R.H., H.K., N.B., A.D.W., E.M.L.), Northwestern University Feinberg School of Medicine, Chicago, IL; and Department of Pediatrics (J.B.), Northwestern University Feinberg School of Medicine, Chicago, IL.

Go to [Neurology.org/N](https://www.neurology.org/N) for full disclosures. Funding information and disclosures deemed relevant by the authors, if any, are provided at the end of the article.

Section 1

A 22-year-old right-handed man with recently diagnosed gout and worsening renal function presented with 3 months of gait instability and cognitive changes. Approximately 5 months before presentation, he was diagnosed with gout, confirmed by uric acid crystals on synovial fluid. He was recommended to start a vegan diet then. He also developed worsening renal function. Until 3 months before presentation, he was a high-functioning student at his university. He then started struggling in classes, stopped interacting with family, stopped going to school, and became more introverted. He became clumsier, with difficulty going upstairs and downstairs. He initially presented to an outside hospital, where an extensive workup was performed, but no clear etiology was found, and he was discharged with a diagnosis of catatonia.

Three months after onset of neurologic symptoms, the patient presented to our institution with worsened condition. He had recently become violent and started having abnormal

movements of his extremities. Two weeks earlier, he had stopped walking and required assistance to move. He was urinating on himself and no longer told his parents when he needed to use the bathroom. There was no significant family history. On neurologic examination, mental status examination was notable for prominent inattention, perseveration, psychomotor slowing, and inappropriate laughter. He could not follow multistep commands and had reduced spontaneous speech with increased latency. Motor examination revealed mild spasticity in the lower greater than upper extremities. Detailed motor and sensory testing were limited by his mental status, but he had at least antigravity strength in the upper and lower extremities bilaterally. His tendon reflexes were 3+ throughout with crossed adductors, and he had bilateral ankle clonus for greater than 10 beats and a positive Hoffman reflex on the left.

Questions for Consideration:

1. What are the localization and broad categories to consider in the differential diagnosis?
2. What diagnostic studies should be ordered initially?

GO TO SECTION 2

Section 2

The multidomain cognitive dysfunction suggests diffuse bilateral cerebral hemispheric involvement, whereas the prominent spasticity, hyperreflexia, and clonus suggest upper motor neuron involvement, specifically within the corticospinal tracts. The bilateral pyramidal tract dysfunction could be localized intracranially, anywhere from the primary motor cortex to the internal capsule on down to the brainstem. Processes that could lead to such a diffuse bihemispheric process leading to cognitive symptoms and gait difficulties broadly include the following: vascular (e.g., CNS vasculitis); infectious and inflammatory (e.g., subacute to chronic meningoencephalitis); neoplastic or paraneoplastic; autoimmune (e.g., autoimmune encephalitis, demyelinating disease); toxic and metabolic (e.g., B₁₂ deficiency leading to subacute combined degeneration)¹; and inborn errors of metabolism, considered initially due to young age and gout history,^{2,3} as summarized in the Table.

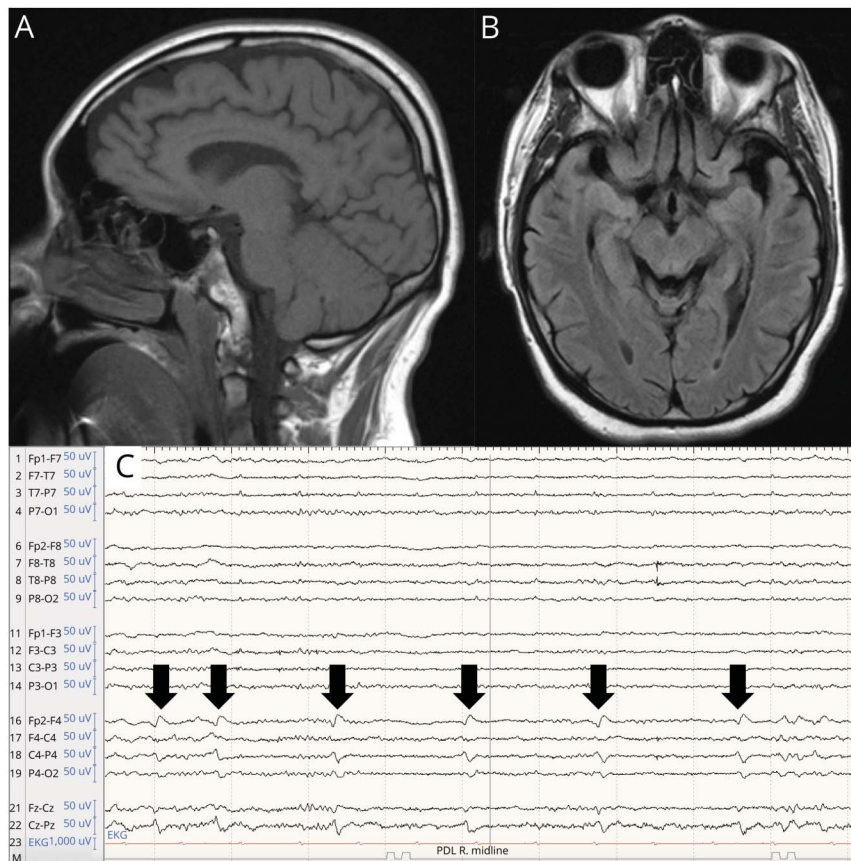
Basic laboratory workup revealed SARS-CoV-2 positivity with lymphopenic leukopenia. B₁₂ was 462 pg/mL and folate >20.0 ng/mL. Uric acid was 6.8 mg/dL (2.3–7.6, normal). An MRI of the brain with and without contrast revealed cortical atrophy (Figure 1) but no other acute findings, and an MRI of the

Table Broad Differential Diagnosis for Diffuse, Bihemispheric Processes Leading to Cognitive Symptoms and Gait Difficulties

Broad diagnostic category	Etiologies
Vascular	CNS vasculitis
Infectious and inflammatory	Subacute/chronic meningoencephalitis, HIV encephalitis, neurosyphilis, neuroborreliosis, neurosarcoidosis, neuropsychiatric lupus
Neoplastic	Intracranial neoplastic disease or paraneoplastic syndrome
Autoimmune	Autoimmune encephalitis, demyelinating disease
Toxic and metabolic, acquired	B ₁₂ deficiency, copper deficiency, heavy metal toxicity
Metabolic, hereditary	Inborn errors of metabolism, e.g., Lesch-Nyhan syndrome, cobalamin C deficiency

cervical spine (not shown) was unremarkable. Continuous EEG (cEEG) monitoring for 48 hours revealed generalized continuous delta slow activity with superimposed faster frequencies. CSF studies revealed normal cell count, protein, glucose, IgG synthesis rate/index, and a negative meningitis panel.

Figure 1 Representative Neuroimaging From the Case



A) Sagittal T1-weighted MRI of the brain and B) axial T2/FLAIR MRI of the brain revealing cortical atrophy; C) continuous video EEG recording sample showing lateralized periodic discharges (black arrows) seen in the right fronto-central region consistent with an area of epileptogenic potential.

Encephalopathy, autoimmune, serum, and CSF panels were ordered. Given the patient's age and recent development of gout and renal dysfunction, urine amino acid analysis was sent.

Question for Consideration:

1. Which entities on the differential are less likely, given this initial workup?

[GO TO SECTION 3](#)

Section 3

Given the bland CSF and MRI brain without enhancement or FLAIR signal changes, meningoencephalitis, CNS vasculitis, demyelinating diseases, and CNS neoplastic processes are less likely. However, paraneoplastic or autoimmune encephalitis can present without MRI abnormalities.⁴ Furthermore, there was a weakly positive serum acetylcholine receptor ganglionic neuronal antibody from the previous institution. While this antibody is classically reported in the setting of autoimmune autonomic ganglionopathy,⁵ it has rarely been associated with predominantly neuropsychiatric presentations of autoimmune encephalitis.⁶ The patient was empirically initiated on IVIG for this possibility while awaiting other laboratory test results. In addition, inborn errors of metabolism remained high in the differential consideration, given

the oddity of gout and inadequately explained renal insufficiency. Normal serum vitamin levels did not exclude the possibility of inborn errors of metabolism because they can classically be normal in these conditions.⁷

The serum and CSF encephalopathy panels returned negative, and the serum NeoComplete Paraneoplastic Evaluation again revealed borderline anti- α 3AChR antibody. Notably, the urine amino acid analysis revealed a peak of homocysteine.

Questions for Consideration:

1. What is the significance of the homocysteine peak on urine amino acid analysis?
2. What further studies should be ordered?

GO TO SECTION 4

Section 4

Elevated urine homocysteine is classically found in the homocystinurias. This finding prompted a serum homocysteine level, which was $>50.0 \mu\text{mol/L}$ (0–14.9, normal range), with the quantitative serum homocysteine measured at $283.3 \mu\text{mol/L}$ (6.1–10.8). Serum homocysteine is a key biochemical marker of disruption of the remethylation pathway. When elevated homocysteine is found, serum methionine and quantitative methylmalonic acid (MMA) levels in the serum should be ordered to isolate the defect in the biochemical pathway of cobalamin metabolism.⁷ Serum MMA was significantly elevated to $452,000 \text{ nmol/L}$ (87–318). Serum methionine was $9 \mu\text{mol/L}$ (16–34). This pattern is the biochemical hallmark of cobalamin C (CblC) deficiency.⁷ Genetic testing revealed 2 heterozygous pathogenic variants in the *MMACHC* gene: c.328_331del (p.Asn110Aspfs*13) and c.482G>A (p.Arg161Gln).

Discussion

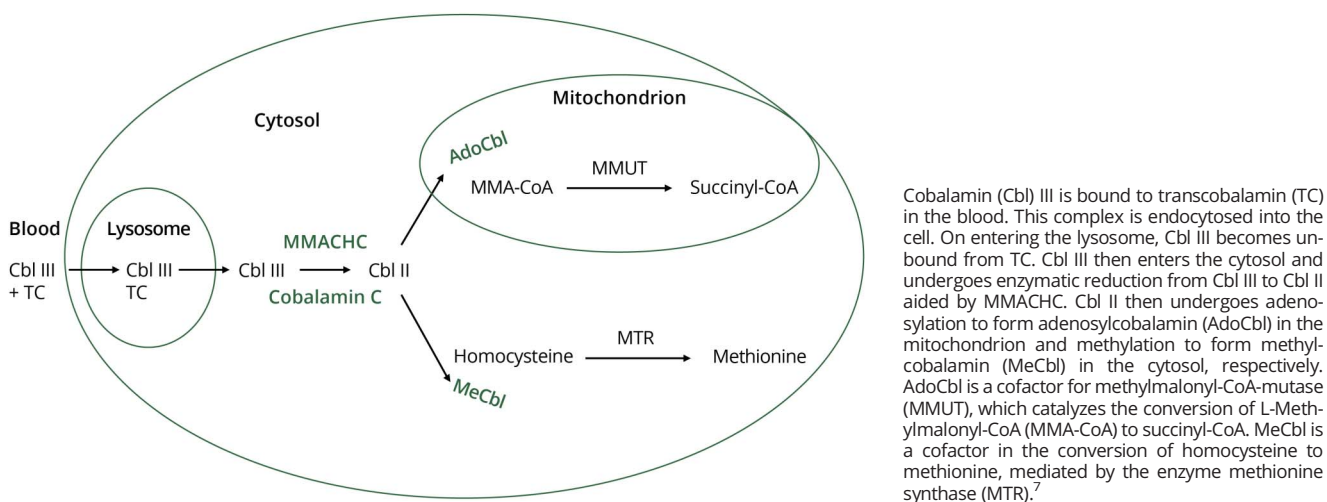
Cobalamin C deficiency is the most common inherited disorder of intracellular cobalamin metabolism.^{8,9} It is most often due to pathogenic variants of the *MMACHC* gene. Because of defective gene product, methylcobalamin and adenosylcobalamin are not produced intracellularly. Methylcobalamin and adenosylcobalamin are critical cofactors for the remethylation of homocysteine to methionine and conversion of MMA to succinic acid, respectively (Figure 2). Thus, the deficiency of methylcobalamin and adenosylcobalamin leads to elevated serum homocysteine and MMA, low methionine levels, and normal serum B₁₂ and folate.⁷

CblC disease is typically classified into 2 forms: early onset (typically within the first year of life)¹⁰ and late onset (which includes late-onset pediatric and adult cases).¹¹ In the past couple of decades, there have been great advancements in newborn

screening for cobalamin deficiencies, but many adults were born before such screening. The late-onset form was first reported in 1970¹² and the adult-onset (aged 18 years or older) form in 2001.¹³ As of 2022, only 45 cases of adult-onset CblC disease have been reported, but this is likely a vast underrepresentation. Whereas early-onset disease has a poor prognosis even with early diagnosis, the adult-onset form generally exhibits robust response to treatment. There is a genotype-phenotype correlation with adult-onset forms tending to have compound heterozygosity of missense variants, which leads to some residual protein function,⁷ as seen in our patient.

In the adult-onset form, neuropathy or myelopathy are the most common clinical signs, followed by ataxia or dysarthria, cognitive decline, psychiatric symptoms, lower limb weakness, and seizures. Other features include thromboembolic disease and kidney failure often due to damage from thrombotic microangiopathy (TMA).^{7,14} Our patient did ultimately develop acute bilateral upper extremity cephalic vein thromboses and a right lower lobe segmental pulmonary embolism, for which he was initiated on therapeutic anticoagulation. He also had elevated creatinine (peak at 3.6–3.8 mg/dL), but the exact etiology of his renal disease was unclear, and he did not have the other accompanying signs of TMA (no hypertension, hematuria, or proteinuria). Kidney biopsy was deferred, given it was unlikely to change management and had elevated risks on therapeutic anticoagulation. In addition, his course was complicated by clinical seizures with left gaze deviation and generalized convulsions. He was reconnected to cEEG, which revealed right fronto-central lateralized periodic epileptiform discharges and seizures without definitive clinical correlation and was initiated on antiseizure medications. Finally, while gout is more commonly associated with inborn errors of metabolism dealing with purine metabolism, it has been reported in cases of methylmalonic acidemia and may be related to decreased renal clearance of uric acid.³

Figure 2 Schematic of Intracellular Cobalamin Metabolism



Cobalamin (Cbl) III is bound to transcobalamin (TC) in the blood. This complex is endocytosed into the cell. On entering the lysosome, Cbl III becomes unbound from TC. Cbl III then enters the cytosol and undergoes enzymatic reduction from Cbl III to Cbl II aided by MMACHC. Cbl II then undergoes adenylation to form adenosylcobalamin (AdoCbl) in the mitochondrion and methylation to form methylcobalamin (MeCbl) in the cytosol, respectively. AdoCbl is a cofactor for methylmalonyl-CoA-mutase (MMUT), which catalyzes the conversion of L-Methylmalonyl-CoA (MMA-CoA) to succinyl-CoA. MeCbl is a cofactor in the conversion of homocysteine to methionine, mediated by the enzyme methionine synthase (MTR).⁷

The treatment for CblC disease is intramuscular or subcutaneous hydroxycobalamin, combined with oral betaine and folic acid.⁷ Of importance, oral cobalamin replacement approaches are ineffective because the patients require supplementation with the active form, which is not absorbed through the oral route; betaine facilitates the conversion of homocysteine to methionine; and folic acid can potentially augment remethylation.⁹ Our patient was initiated on this regimen soon after the biochemical markers confirmed the diagnosis. He improved significantly while still inpatient and was discharged to an inpatient acute rehabilitation facility. By approximately a month after discharge, he could hold an in-depth follow-up conversation over the phone, felt his cognition had significantly improved, and was able to stand and walk for 7–8 meters at a time. This case serves as a reminder to trust the neurologic examination, even if neuroimaging and other workup are unrevealing. In addition, in complicated cases, red herrings may arise,¹⁵ such as the AChR ganglionic antibody, not considered the pathogenic antibody in this case. Finally, the case reminds one to include the inborn errors of metabolism in the differential for young adult patients with onset of neurologic and psychiatric presentations, particularly when accompanied by other systemic findings.

Study Funding

The authors report no targeted funding.

Disclosure

The authors report no disclosures relevant to the manuscript. Go to [Neurology.org/N](https://www.neurology.org/N) for full disclosures.

Publication History

Received by *Neurology* April 27, 2022. Accepted in final form September 16, 2022. Submitted and externally peer reviewed. The handling editor was Whitley Aamodt, MD, MPH.

Appendix Authors

Name	Location	Contribution
Brian Stamm, MD	Ken & Ruth Davee Department of Neurology, Northwestern University Feinberg School of Medicine, Chicago, IL	Drafting/revision of the article for content, including medical writing for content; major role in the acquisition of data; study concept or design; and analysis or interpretation of data
Rebecca DiBiase, MD, MPH	Ken & Ruth Davee Department of Neurology, Northwestern University Feinberg School of Medicine, Chicago, IL	Drafting/revision of the article for content, including medical writing for content; study concept or design
Glenn Ryan Harris, MD	Ken & Ruth Davee Department of Neurology, Northwestern University Feinberg School of Medicine, Chicago, IL	Drafting/revision of the article for content, including medical writing for content

Appendix (continued)

Name	Location	Contribution
Hagop Kaprielian, MD	Ken & Ruth Davee Department of Neurology, Northwestern University Feinberg School of Medicine, Chicago, IL	Drafting/revision of the article for content, including medical writing for content
Nupur Brahmhatt, MD	Ken & Ruth Davee Department of Neurology, Northwestern University Feinberg School of Medicine, Chicago, IL	Drafting/revision of the article for content, including medical writing for content
Allan D Wu, MD	Ken & Ruth Davee Department of Neurology, Northwestern University Feinberg School of Medicine, Chicago, IL	Drafting/revision of the article for content, including medical writing for content
Joshua Baker, DO	Department of Pediatrics, Northwestern University Feinberg School of Medicine, Chicago, IL	Drafting/revision of the article for content, including medical writing for content; study concept or design; and analysis or interpretation of data
Eric M Liotta, MD, MS	Ken & Ruth Davee Department of Neurology, Northwestern University Feinberg School of Medicine, Chicago, IL	Drafting/revision of the article for content, including medical writing for content; study concept or design; and analysis or interpretation of data

References

1. Qudsiya Z, De Jesus O. Subacute combined degeneration of the spinal cord. In: *StatPearls*. StatPearls Publishing; 2021:1.
2. Doucet BP, Jegatheesan D, Burke J. Late diagnosis of Lesch-Nyhan disease variant. *BMJ Case Rep*. 2013;2013:1-2. doi:10.1136/bcr-2013-201997
3. Charuvanij S, Pattaragarn A, Wisuthsarewong W, Vatanavicharn N. Juvenile gout in methylmalonic acidemia. *Pediatr Int*. 2016;58(6):501-503.
4. Titulaer MJ, McCracken L, Gabilondo I, et al. Treatment and prognostic factors for long-term outcome in patients with anti-NMDA receptor encephalitis: an observational cohort study. *Lancet Neurol*. 2013;12(2):157-165.
5. Vernino S. Autoimmune autonomic disorders. *Continuum*. 2020;26(1):44-57.
6. McKeon A, Lennon VA, Lachance DH, Fealey RD, Pittock SJ. Ganglionic acetylcholine receptor autoantibody. *Arch Neurol*. 2009;66(6):735-741. doi:10.1001/archneurol.2009.78
7. Kalantari S, Brezzi B, Bracciamà V, et al. Adult-onset CblC deficiency: a challenging diagnosis involving different adult clinical specialists. *Orphanet J Rare Dis*. 2022;17(1):33.
8. Mudd SH, Levy HL, Abeles RH. A derangement in B12 metabolism leading to homocystinemia, cystathioninemia and methylmalonic aciduria. *Biochem Biophys Res Commun*. 1969;35(1):121-126.
9. Sloan JL, Carrillo N, Adams D, Venditti CP. Disorders of intracellular cobalamin metabolism. In: Adam MP, Ardinger HH, Pagon RA, et al., eds. *GeneReviews*. University of Washington; 2008.
10. Wang SJ, Yan CZ, Wen B, Zhao YY. Clinical feature and outcome of late-onset cobalamin C disease patients with neuropsychiatric presentations: a Chinese case series. *Neuropsychiatr Dis Treat*. 2019;15:549-555.
11. Huemer M, Scholl-Bürgi S, Hadaya K, et al. Three new cases of late-onset cblC defect and review of the literature illustrating when to consider inborn errors of metabolism beyond infancy. *Orphanet J Rare Dis*. 2014;9:161.
12. Goodman SI, Moe PG, Hammond KB, Mudd SH, Uhlenhuth BW. Homocystinuria with methylmalonic aciduria: two cases in a sibship. *Biochem Med*. 1970;4(5):500-515.
13. Bodamer OA, Rosenblatt DS, Appel SH, Beaudet AL. Adult-onset combined methylmalonic aciduria and homocystinuria (cblC). *Neurology*. 2001;56(8):1113.
14. Lemoine M, François A, Grangé S, et al. Cobalamin C deficiency induces a typical histopathological pattern of renal arteriolar and glomerular thrombotic microangiopathy. *Kidney Int Rep*. 2018;3(5):1153-1162.
15. Ebright MJ, Li SH, Reynolds E, et al. Unintended consequences of Mayo paraneoplastic evaluations. *Neurology*. 2018;91(22):e2057-e2066.

Neurology[®]

Clinical Reasoning: A Young Adult Man With Cognitive Changes, Gait Difficulty, and Renal Insufficiency

Brian Stamm, Rebecca DiBiase, Glenn Ryan Harris, et al.

Neurology 2023;100:206-212 Published Online before print November 2, 2022

DOI 10.1212/WNL.0000000000201500

This information is current as of November 2, 2022

Updated Information & Services	including high resolution figures, can be found at: http://n.neurology.org/content/100/4/206.full
References	This article cites 13 articles, 2 of which you can access for free at: http://n.neurology.org/content/100/4/206.full#ref-list-1
Subspecialty Collections	This article, along with others on similar topics, appears in the following collection(s): All Clinical Neurology http://n.neurology.org/cgi/collection/all_clinical_neurology All Genetics http://n.neurology.org/cgi/collection/all_genetics All Neuropsychology/Behavior http://n.neurology.org/cgi/collection/all_neuropsychology_behavior All Pediatric http://n.neurology.org/cgi/collection/all_pediatric Metabolic disease (inherited) http://n.neurology.org/cgi/collection/metabolic_disease_inherited
Permissions & Licensing	Information about reproducing this article in parts (figures, tables) or in its entirety can be found online at: http://www.neurology.org/about/about_the_journal#permissions
Reprints	Information about ordering reprints can be found online: http://n.neurology.org/subscribers/advertise

Neurology® is the official journal of the American Academy of Neurology. Published continuously since 1951, it is now a weekly with 48 issues per year. Copyright © 2022 American Academy of Neurology. All rights reserved. Print ISSN: 0028-3878. Online ISSN: 1526-632X.

