

# Teaching NeuroImage: Subacute Quadriparesis From Intramedullary Spinal Cord Infiltrating Glioma With *TERT* Promoter Mutation

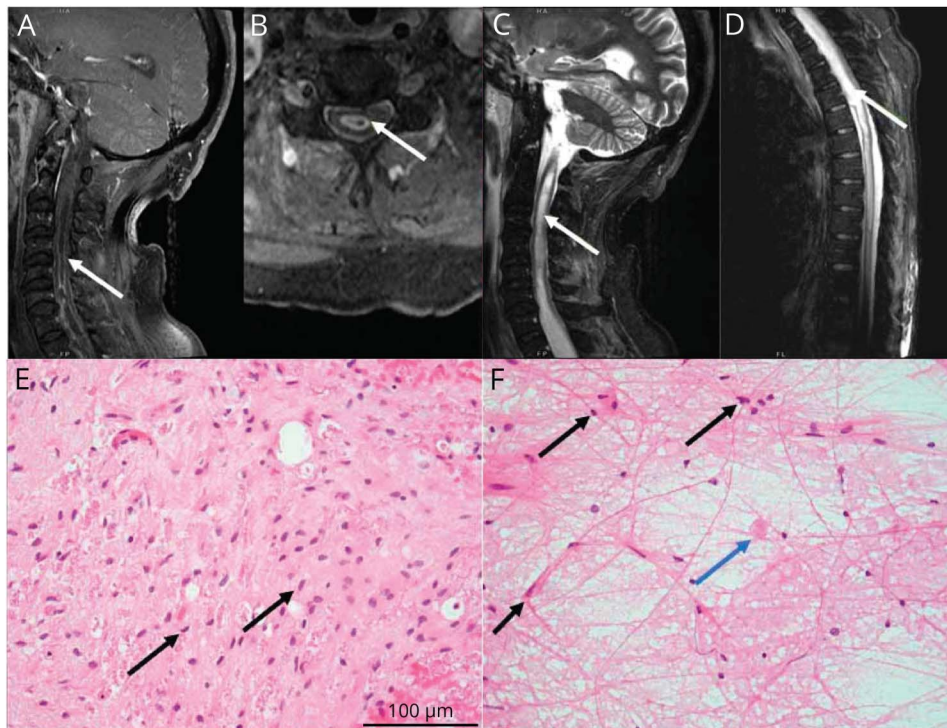
Simon Gritsch, DrMed, MD, Yasmin Aghajan, MD, Liana Kozanno, MD, PhD, Daniel Chiu, MD, MPH, Justin T. Jordan, MD, MPH, Matthew P. Frosch, MD, PhD, Ganesh Shankar, MD, PhD, and W. Taylor Kimberly, MD, PhD

## Correspondence

Dr. Aghajan  
yaghajan@partners.org

*Neurology*® 2023;100:1164-1165. doi:10.1212/WNL.0000000000207148

**Figure** MRI of Cervical and Thoracic Cord and H&E Sections From Thoracic Cord Biopsy



Spinal MRI reveals an expansile, intramedullary T2 hyperintense signal abnormality, with peripheral nodular enhancement spanning C4-T5 (A, B), and longitudinally extensive expansion of the central canal from obex to T11 (C, D). H&E sections at 400× magnification show infiltrating glioma with moderately pleomorphic, hyperchromatic cells with piloid processes (E, F black arrows) and occasional eosinophilic granular bodies (F, blue arrow). H&E = hematoxylin and eosin.

A 68-year-old man without a medical history developed 2 months of progressive weakness and cervicalgia. Examination showed quadriparesis with T10 sensory level. Spine MRI revealed an expansile intramedullary lesion from obex to T11 with peripheral nodular enhancement (Figure, A–D). Brain MRI, body PET/CT, and broad serum diagnostics were normal (eTable 1, [links.lww.com/WNL/C653](https://links.lww.com/WNL/C653)). CSF showed protein 2,505 mg/dL, 0 cells/μL, glucose 88 mg/dL, and CSF cell-free DNA sequencing identified a pathogenic variant in *TERT* p.C250T, suspicious for glioma.<sup>1</sup> Thoracic spinal cord biopsy was pursued to exhaust reversible etiologies and revealed infiltrating glioma with *TERT* promoter mutation (Figure, E and F). Owing to progressive quadriplegia, respiratory failure, and poor prognosis, care was directed toward comfort.

## MORE ONLINE

### Teaching slides

[links.lww.com/WNL/C654](https://links.lww.com/WNL/C654)

From the Department of Neurology (S.G., Y.A., D.C., J.T.J., W.T.K.), Department of Pathology (L.K., M.P.F.), and Department of Neurosurgery (G.S.), Massachusetts General Hospital, Boston. Go to [Neurology.org/N](https://Neurology.org/N) for full disclosures. Funding information and disclosures deemed relevant by the authors, if any, are provided at the end of the article.

Spinal masses are classified as extradural, intradural extramedullary, or intradural intramedullary.<sup>2</sup> Differential diagnosis for intramedullary cord lesions includes demyelination, paraneoplastic myelopathies (e.g., anti-CRMP5), neurosarcoidosis, infection, vascular abnormalities (e.g., dural arteriovenous fistula/malformation), nutritional deficiency, toxic insult, or tumor. Although noninvasive diagnostics should be exhausted, definitive diagnosis of neoplastic myelopathy generally requires biopsy. Novel cell-free DNA sequencing may complement or eventually supersede certain diagnostics, especially where biopsy is unsafe.

### Author Contributions

S. Gritsch: drafting/revision of the manuscript for content, including medical writing for content; major role in the acquisition of data; study concept or design; and analysis or interpretation of data. Y. Aghajan: drafting/revision of the manuscript for content, including medical writing for content; major role in the acquisition of data; study concept or design; and analysis or interpretation of data. L. Kozanno: drafting/revision of the manuscript for content, including medical writing for content; major role in the acquisition of data; study concept or design; and analysis or interpretation of data. D. Chiu: drafting/revision of the manuscript for content, including medical writing for content; major role in the acquisition of data; study concept or design; and analysis or interpretation of data. J. T. Jordan: drafting/revision of the manuscript for content, including medical writing for content; major role in the acquisition of data; study concept or design; and analysis or interpretation of data. M. P. Frosch: drafting/revision of the manuscript for content, including medical writing for content; major role in the acquisition of data; study concept or design; and analysis or interpretation of data. G. Shankar: drafting/revision of

the manuscript for content, including medical writing for content; major role in the acquisition of data; study concept or design; and analysis or interpretation of data. W. Taylor Kimberly: drafting/revision of the manuscript for content, including medical writing for content; major role in the acquisition of data; study concept or design; and analysis or interpretation of data.

### Study Funding

No targeted funding reported.

### Disclosure

S. Gritsch, Y. Aghajan, L. Kozanno, and D. Chiu report no disclosures relevant to the manuscript. J.T. Jordan reports consulting income from Navio Theragnostics, Recursion Pharmaceuticals, and CEC Oncology, holds stock in Navio Theragnostics and The Doctor Lounge, and receives royalties from Elsevier. M.P. Frosch and G. Shankar report no disclosures relevant to the manuscript. W.T. Kimberly reports consulting fees from NControl Therapeutics, research grants from Biogen, and equity in Woolsey Pharmaceuticals. Go to [Neurology.org/N](https://www.neurology.org/N) for full disclosures.

### Publication History

Received by *Neurology* October 5, 2022. Accepted in final form January 19, 2023. Submitted and externally peer reviewed. The handling editor was Resident and Fellow Section Editor Whitley Aamodt, MD, MPH.

### References

1. Zadnik PL, Gokaslan ZL, Burger PC, Bettegowda C. Spinal cord tumours: advances in genetics and their implications for treatment. *Nat Rev Neurol*. 2013;9(5):257-266. doi:10.1038/NRNEUROL.2013.48
2. Pruitt AA. Neoplastic myelopathies. *Continuum (Minneapolis)*. 2021;27(1):121-142. doi:10.1212/CON.0000000000000964

---

## The *Neurology*<sup>®</sup> Null Hypothesis Online Collection...

### Contributing to a transparent research reporting culture!



The *Neurology* journals have partnered with the Center for Biomedical Research Transparency (CBMRT) to promote and facilitate transparent reporting of biomedical research by ensuring that all biomedical results—including negative and inconclusive results—are accessible to researchers and clinicians in the interests of full transparency and research efficiency.

*Neurology*'s Null Hypothesis Collection is a dedicated online section for well conducted negative, inconclusive, or replication studies. View the collection at: [NPub.org/NullHypothesis](https://www.neurology.org/NPub.org/NullHypothesis)

# Neurology<sup>®</sup>

## Teaching NeuroImage: Subacute Quadriparesis From Intramedullary Spinal Cord Infiltrating Glioma With *TERT* Promoter Mutation

Simon Gritsch, Yasmin Aghajan, Liana Kozanno, et al.

*Neurology* 2023;100;1164-1165 Published Online before print February 20, 2023

DOI 10.1212/WNL.0000000000207148

**This information is current as of February 20, 2023**

<b>Updated Information &amp; Services</b>	including high resolution figures, can be found at: <a href="http://n.neurology.org/content/100/24/1164.full">http://n.neurology.org/content/100/24/1164.full</a>
<b>References</b>	This article cites 2 articles, 0 of which you can access for free at: <a href="http://n.neurology.org/content/100/24/1164.full#ref-list-1">http://n.neurology.org/content/100/24/1164.full#ref-list-1</a>
<b>Subspecialty Collections</b>	This article, along with others on similar topics, appears in the following collection(s): <b>All Oncology</b> <a href="http://n.neurology.org/cgi/collection/all_oncology">http://n.neurology.org/cgi/collection/all_oncology</a> <b>All Spinal Cord</b> <a href="http://n.neurology.org/cgi/collection/all_spinal_cord">http://n.neurology.org/cgi/collection/all_spinal_cord</a> <b>MRI</b> <a href="http://n.neurology.org/cgi/collection/mri">http://n.neurology.org/cgi/collection/mri</a> <b>Spinal cord tumor</b> <a href="http://n.neurology.org/cgi/collection/spinal_cord_tumor">http://n.neurology.org/cgi/collection/spinal_cord_tumor</a>
<b>Permissions &amp; Licensing</b>	Information about reproducing this article in parts (figures, tables) or in its entirety can be found online at: <a href="http://www.neurology.org/about/about_the_journal#permissions">http://www.neurology.org/about/about_the_journal#permissions</a>
<b>Reprints</b>	Information about ordering reprints can be found online: <a href="http://n.neurology.org/subscribers/advertise">http://n.neurology.org/subscribers/advertise</a>

*Neurology*® is the official journal of the American Academy of Neurology. Published continuously since 1951, it is now a weekly with 48 issues per year. Copyright © 2023 American Academy of Neurology. All rights reserved. Print ISSN: 0028-3878. Online ISSN: 1526-632X.

