

Clinical Reasoning: A 39-Year-Old Man With Asymmetric Distal Weakness and Loss of Sensitivity

Valentin Loser, MD, Gabriela Blanchard, MD, Emmanuella Guenova, MD, Marie Théaudin, MD, and Alex Vicino, MD

Neurology® 2023;100:88-93. doi:10.1212/WNL.0000000000201410

Correspondence

Dr. Loser
valentin.loser@chuv.ch

Abstract

A 39-year-old man presented with an asymmetric distal weakness and loss of sensitivity sequentially affecting both lower extremities and the left upper limb. Nerve conduction studies showed a multifocal sensory and motor axonal neuropathy, and a pseudo-conduction block of the right fibular nerve, the whole being consistent with a mononeuropathy multiplex. An uncommon etiology was found after an extensive workup. Axonal loss was severe, with only partial response to treatment with corticosteroids and IV immunoglobulins.

Section 1

A 39-year-old man developed transient fever, headache, and night sweats. After 2 weeks, he experienced sensory loss in the left leg and dorsal foot on awakening. A few hours later, the sensory deficit extended to the sole of the left foot, and the following day, he had the same symptoms in the right foot. Two days later, he rapidly developed weakness of left foot plantar flexion, and 3 days later, of right foot dorsiflexion. The symptoms were initially painless, but he secondarily developed severe neuropathic pain of both lower extremities. At this time, he did not have any additional symptoms suggestive of systemic involvement. He then presented to the emergency department.

At admission, 9 days after symptom onset, vital parameters were within normal limits. General examination showed slightly painful erythematous papules and nodules on the front of both legs. On neurologic examination, there was severe paresis of right foot dorsiflexion (M2) and eversion (M3), left foot flexion and inversion (M4). Left Achilles reflex was absent. Plantar responses were in flexion. There was decreased sensation to touch and pain in both superficial fibular territories and anesthesia in the left plantar nerve territory. The initial workup disclosed a discrete inflammatory syndrome (erythrocyte sedimentation rate 35 mm/h and C-reactive protein <5 mg/L) and a normocytic normochromic anemia.

Questions for Consideration:

1. Where do you localize the affection in the nervous system?
2. What diagnostic test would you first perform?

GO TO SECTION 2

From the Nerve-Muscle Unit (V.L., M.T., A.V.), Neurology Service, Department of Clinical Neurosciences, Lausanne University Hospital and University of Lausanne; and Dermatology Service (G.B., E.G.), Lausanne University Hospital and University of Lausanne, Switzerland.

Go to [Neurology.org/N](https://www.neurology.org/N) for full disclosures. Funding information and disclosures deemed relevant by the authors, if any, are provided at the end of the article.

Section 2

Sensory and motor impairment in both lower limbs may suggest a myelopathy. However, the absence of upper motor neuron signs and sphincter disturbance rather suggest a peripheral neuropathy.

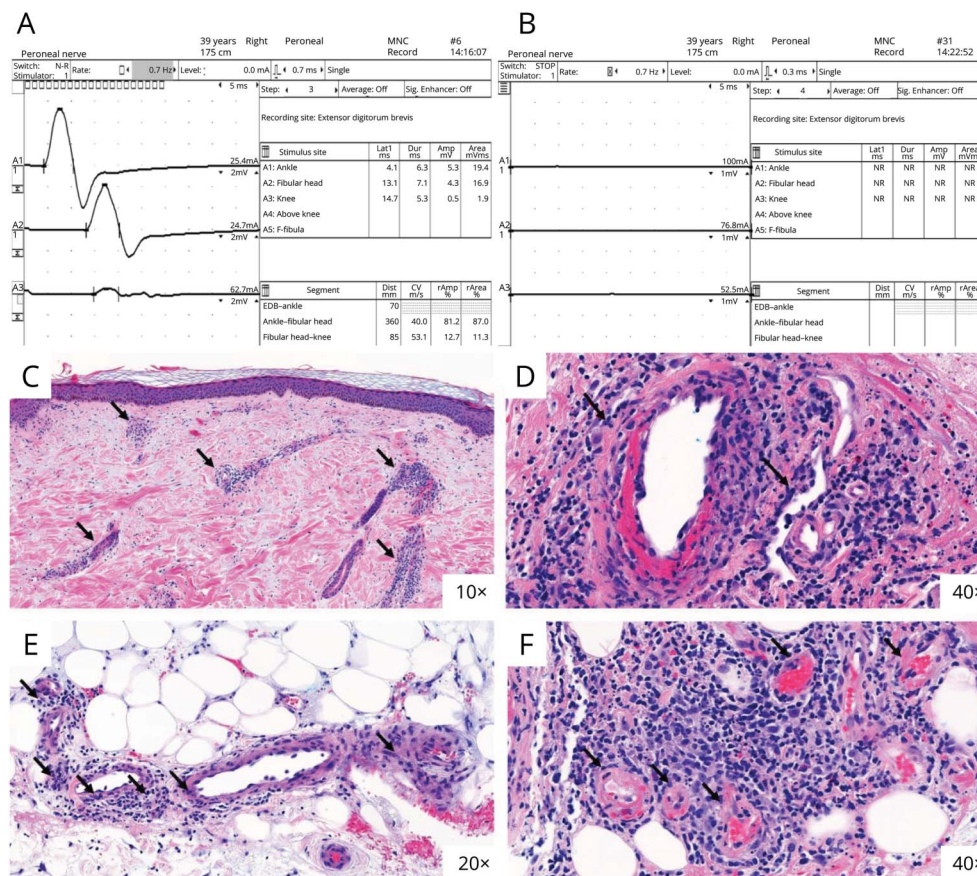
Nerve conduction studies (NCSs) performed 9 days after symptom onset showed an asymmetric peripheral neuropathy,

with a motor conduction block in the right fibular nerve above the fibular head (Figure, A) and a reduced amplitude of the left sural and superficial fibular sensory nerve action potentials (SNAPs). Other studied nerves were normal (eTable 1, links. www.com/WNL/C438).

Questions for Consideration:

1. What is the most likely syndromic diagnosis?
2. What additional test would you perform to confirm diagnosis?

Figure Nerve Conduction Study and Skin Biopsy of a Left Pretibial Erythematous Lesion



GO TO SECTION 3

Section 3

The disease presented with rapidly progressing, asymmetric, multiple-trunk sensory-motor nerve involvement. NCSs showed a multifocal sensory and motor axonal neuropathy, suggestive of mononeuropathy multiplex. The differential diagnosis included the multifocal variant of inflammatory demyelinating polyradiculoneuropathy. However, the onset of symptoms within a few days and the axonal neuropathy pattern refute this hypothesis.

Conduction block describes the physiologic phenomenon in which saltatory conduction is blocked at a point of the nerve and is defined as a loss of amplitude/area of the compound motor action potential (CMAP) on proximal stimulation compared with distal stimulation. The amplitude/area reduction has to range from 20% to 50%, depending on the set of criteria used.¹ Usually, conduction block is a sign of focal demyelination, which can be seen in inflammatory demyelinating neuropathies, like Guillain-Barré syndrome, or be a consequence of focal ion channel dysfunction in nodo-

paranodopathies. In the event of a recent axonal interruption, such as nerve trauma or ischemic damage, a transient conduction block may be observed during the first few days following the lesion. Indeed, the distal extremities of the nerves remain capable of conducting impulses for a few days before the Wallerian degeneration process is completed. The conduction block is therefore transient (pseudo-conduction block) and will later give way to a decrease in the amplitude of the distal CMAP response.²

Mononeuropathy multiplex, especially when associated with pain and systemic involvement, should suggest a vasculitic process. We therefore performed a skin biopsy of the pretibial lesions, which showed a small- and medium-sized vessels necrotizing vasculitis, including fibrinoid necrosis of the vascular wall (Figure, C–F).

Questions for Consideration:

1. What are the most common etiologies of mononeuropathy multiplex?
2. What diagnostic tests would you perform?

GO TO SECTION 4

Section 4

In most cases, mononeuropathy multiplex is one of the manifestations of a primary systemic vasculitis, affecting small- or medium-sized vessels, including polyarteritis nodosa, antineutrophil cytoplasmic antibody (ANCA)-associated vasculitis, and cryoglobulinemic vasculitis. Vasculitis can also be secondary to a systemic immunologic disease, an infection, some drugs, or malignancy (Table). Finally, it can only affect the peripheral nervous system, without an obvious trigger, which is defined as a non-systemic vasculitic neuropathy.³

The workup should include a broad immunologic blood work, including antinuclear antibodies (ANA), ANCA, rheumatoid factor, anti-Ro/SSA and anti-La/SSB antibodies and cryoglobulins, and an infectious screening, including HIV, syphilis, Lyme, and hepatitis B, C, and E virus serologies. A more thorough

Table Most Common Etiologies of Vasculitic Neuropathies⁴

Primary systemic vasculitides	ANCA-associated vasculitis:
	Microscopic polyangiitis
	Eosinophilic granulomatosis with polyangiitis (EGPA, formerly Churg-Strauss syndrome)
	Granulomatosis with polyangiitis (GPA, formerly Wegener granulomatosis)
	Essential mixed cryoglobulinemia
Polyarteritis nodosa	
Secondary systemic vasculitides	Connective tissue diseases:
	Rheumatoid arthritis
	Systemic lupus erythematosus
	Sjögren syndrome
	Systemic sclerosis
	Mixed connective tissue disease
	Dermatomyositis
	Other systemic diseases:
Sarcoidosis	

Table Most Common Etiologies of Vasculitic Neuropathies⁴ (continued)

Behçet disease
Inflammatory bowel disease
Infections:
Hepatitis B, C, and E virus, CMV, EBV, HSV, HIV, HTLV-1, and parvovirus B19
Leprosy
Lyme disease
Drugs
Malignancy
Nonsystemic vasculitic neuropathy Including:
Postsurgical inflammatory neuropathy
Wartenberg migratory sensory neuropathy
Diabetic radiculoplexus neuropathy

Adapted with permission from Wolters Kluwer Health, Inc.: Karam C. Peripheral Neuropathies Associated With Vasculitis and Autoimmune Connective Tissue Disease. *Continuum (Minneapolis)*. 2020;26(5):1257–1279.

infectious workup may be performed depending on the exposure. If systemic vasculitis is suspected, chest and abdomen CT is also indicated to look for systemic involvement.

In our patient, immunologic assessment, including ANA, ANCA, and cryoglobulins, was negative. CSF examination did not show any abnormality. Chest and abdomen CT showed multiple pulmonary nodules and micronodules and mesenteric and retroperitoneal lymph nodes. Infectious tests were negative, apart from a positive parvovirus B19 serology (IgG index 35, norm <1.1 and IgM index 1.9 norm <1.1). We performed a biopsy of the right peroneus brevis muscle, which was within normal limits. A PCR for parvovirus B19 was positive in the muscle sample, but negative in the skin biopsy, which could be related to patchy vasculitis involvement. We therefore made a diagnosis of possible parvovirus B19-associated small- and medium-sized vessels necrotizing vasculitis.

Question for Consideration:

1. How would you treat the patient?

GO TO SECTION 5

Section 5

The general principle of treatment of vasculitic neuropathy is the rapid introduction of immunosuppressive therapy to prevent further nerve damage. The standard initial therapy is high-dose corticosteroid, usually by prednisone (1.0 mg/kg/d), which may be preceded in severe cases by IV methylprednisolone (500–1,000 mg/d for 3–5 days).³ The introduction of maintenance immunosuppressive therapy then depends on the etiologic diagnosis.

Twelve days after symptom onset, we introduced a course of IV methylprednisolone (500 mg/d) for 3 days, with oral prednisone relay (1 mg/kg/d). During the first 3 days of treatment, the patient kept clinically worsening, with complete paresis of right foot dorsiflexion. Five days after corticosteroid initiation, he developed a left proximal sensory-motor median neuropathy. Hence, treatment with IV immunoglobulin (IVIg) was immediately introduced (2 g/kg over 5 days). A few days after IVIg initiation, there was already an improvement of the sensory-motor symptoms of the left upper limb and a slight improvement of the sensory symptoms in the lower limbs. Motor impairment in lower limbs did not progress further. The patient was then discharged home with a tapering prednisone therapy.

At follow-up, 1 month after discharge, the patient reported a slight improvement of the sensory symptoms of the lower extremities, but persistence of important motor disability. On neurologic examination, he had severe paresis of right foot and hallux dorsiflexion (M1) and eversion (M2), mild paresis of left foot flexion, inversion, and hallux dorsiflexion (M4+), and severe paresis of left hallux flexion (M1). There was hypoesthesia of left median nerve territory, of both superficial fibular nerve territories and anesthesia of left plantar nerve territory. NCSs showed diffuse new axonal loss of several nerves, with abolition of right fibular (Figure B) and left tibial nerve CMAP, reduction of left fibular and median nerve and right tibial nerve CMAP amplitude, reduction of the left median and right sural nerve SNAP amplitude, and an abolition of the left sural and both superficial fibular SNAPs (eTable 1, links.lww.com/WNL/C438).

Discussion

Here, we report a case of small- and medium-sized vessel necrotizing vasculitis characterized by mononeuropathy multiplex, skin, and systemic involvement, probably associated with an acute parvovirus B19 infection. Treatment with corticosteroids was ineffective, and treatment with 1 cycle of IVIg 2 g/kg allowed a partial improvement. The nerve damage was severe, as evidenced by the significant axonal loss displayed by follow-up NCSs. We performed a third NCS 3 months after discharge, which did not display any progression of the axonal loss. Thus, IVIg treatment probably stopped the underlying vasculitic mechanism and stabilized the axonal

neuropathy, nevertheless leaving motor sequelae secondary to the initial axonal damage.

Mononeuropathy multiplex is generally the consequence of a vasculitic phenomenon, producing an inflammation of the small caliber vessel wall involved in nerve vascularization (vasa nervorum) and leading to ischemia and infarction of the nerve. Nerve vasculitis can be proven histologically by a nerve-muscle biopsy, usually the sural or superficial peroneal nerve, with a sensitivity between 50% and 60%.^{3,5} If a diagnosis of systemic vasculitis that included a biopsy of another involved organ is established, nerve biopsy can be avoided.

Several viruses have been implicated in mononeuropathy multiplex, either by a direct cytopathic mechanism or an indirect autoimmune response.^{6–8} Parvovirus B19 infection has been reported in some patients with necrotizing vasculitis and has been involved in several central and peripheral nervous system complications including some cases of mononeuropathy multiplex.^{9–12}

The diagnosis of mononeuropathy multiplex is clinical; NCSs are useful in confirming the multifocal axonal neuropathy. The presence of pseudo-conduction block has been described in this pathology.²

Mononeuropathy multiplex is a neurologic emergency, the vasculitic mechanism at its origin often leading to irreversible ischemia and necrosis of the affected nerve. The introduction of immunotherapy, especially high-dose corticosteroids, should therefore be done immediately on suspicion. Parvovirus B19-associated vasculitis with mononeuropathy multiplex appears to respond poorly to corticosteroids but pretty well to treatment with IVIg, which may suggest an antiviral mechanism of IVIg in addition to the expected delayed immunomodulatory effect.^{13,14}

Study Funding

The authors report no targeted funding.

Disclosure

The authors report no disclosures relevant to the manuscript. Go to Neurology.org/N for full disclosures.

Publication History

Received by *Neurology* May 13, 2022. Accepted in final form August 30, 2022. Submitted and externally peer reviewed. The handling editor was Whitley Aamodt, MD, MPH.

Appendix Authors

Name	Location	Contribution
Valentin Loser, MD	Nerve-Muscle Unit, Neurology Service, Department of Clinical Neurosciences, Lausanne University Hospital and University of Lausanne	Drafting/revision of the manuscript for content, including medical writing for content, and major role in the acquisition of data

Appendix (continued)

Name	Location	Contribution
Gabriela Blanchard, MD	Dermatology Service, Lausanne University Hospital and University of Lausanne	Drafting/revision of the manuscript for content, including medical writing for content
Emmanuella Guenova, MD	Dermatology Service, Lausanne University Hospital and University of Lausanne	Drafting/revision of the manuscript for content, including medical writing for content
Marie Théaudin, MD	Nerve-Muscle Unit, Neurology Service, Department of Clinical Neurosciences, Lausanne University Hospital and University of Lausanne	Drafting/revision of the manuscript for content, including medical writing for content
Alex Vicino, MD	Nerve-Muscle Unit, Neurology Service, Department of Clinical Neurosciences, Lausanne University Hospital and University of Lausanne	Drafting/revision of the manuscript for content, including medical writing for content, and major role in the acquisition of data

References

1. Lewis RA. Neuropathies associated with conduction block. *Curr Opin Neurol*. 2007; 20(5):525-530.
2. McCluskey L, Feinberg D, Cantor C, Bird S. Pseudo-conduction block" in vasculitic neuropathy. *Muscle Nerve*. 1999;22(10):1361-1366.
3. Gwathmey KG, Burns TM, Collins MP, Dyck PJB. Vasculitic neuropathies. *Lancet Neurol*. 2014;13(1):67-82.
4. Karam C. Peripheral neuropathies associated with vasculitis and autoimmune connective tissue disease. *Continuum (Minneapolis, Minn)* 2020;26(5):1257-1279.
5. Collins MP, Mendell JR, Periquet MI, et al. Superficial peroneal nerve/peroneus brevis muscle biopsy in vasculitic neuropathy. *Neurology*. 2000;55(5):636-643.
6. Pai B S, Pai K. Livedoid vasculopathy and mononeuritis multiplex, with a fulminant hepatic failure which was caused by herpes simplex hepatitis: a case report. *J Clin Diagn Res*. 2013;7(5):921-923P.
7. Palma P, Costa A, Duro R, Neves N, Abreu C, Sarmento A. Mononeuritis multiplex: an uncommon neurological manifestation of cytomegalovirus reactivation in an HIV-infected patient. *BMC Infect Dis*. 2018;18(1):554.
8. Johnston P, Akili S, Khan A. Mononeuritis multiplex associated with primary EBV infection. *Clin Infect Pract*. 2022;13:100128.
9. Young NS, Brown KE. Parvovirus B19. *N Engl J Med*. 2004;350(6):586-597.
10. Finkel TH, Török TJ, Ferguson PJ, et al. Chronic parvovirus B19 infection and systemic necrotizing vasculitis: opportunistic infection or aetiological agent? *Lancet (London, England)*. 1994;343(8908):1255-1258.
11. Barah F, Whiteside S, Batista S, Morris J. Neurological aspects of human parvovirus B19 infection: a systematic review. *Rev Med Virol*. 2014;24(3):154-168.
12. Lenglet T, Haroche J, Schnuriger A, et al. Mononeuropathy multiplex associated with acute parvovirus B19 infection: characteristics, treatment and outcome. *J Neurol*. 2011;258(7):1321-1326.
13. Fargeot G, Périllaud-Dubois C, Deback C, et al. Parvovirus B19-related peripheral nerve necrotizing vasculitis following SARS-CoV-2 infection. *Rev Neurol (Paris)* 2021. S0035-3787(21)00624-X.

Share Your Artistic Expressions in Neurology ‘Visions’

AAN members are urged to submit medically or scientifically related artistic images, such as photographs, photomicrographs, and paintings, to the “Visions” section of *Neurology*®. These images are creative in nature, rather than the medically instructive images published in the NeuroImages section. The image or series of up to six images may be black and white or color and must fit into one published journal page. Accompanying description should be 100 words or less; the title should be a maximum of 140 characters including spaces and punctuation.

Please access the Author Center at [NPub.org/authors](https://www.npub.org/authors) for full submission information.

Announcing...

Child Neurology: A Case-Based Approach Cases From the Neurology® Resident & Fellow Section

This collaboration between the American Academy of Neurology (AAN) and the Child Neurology Society (CNS) represents a collection of reprinted cases from the past 15 years from the Neurology Resident & Fellow Section.

An invaluable resource for both adult and pediatric neurologists and trainees! FREE download: [NPub.org/cnbook](https://www.npub.org/cnbook)

Neurology[®]

Clinical Reasoning: A 39-Year-Old Man With Asymmetric Distal Weakness and Loss of Sensitivity

Valentin Loser, Gabriela Blanchard, Emmanuella Guenova, et al.
Neurology 2023;100:88-93 Published Online before print October 18, 2022
DOI 10.1212/WNL.0000000000201410

This information is current as of October 18, 2022

Updated Information & Services	including high resolution figures, can be found at: http://n.neurology.org/content/100/2/88.full
References	This article cites 12 articles, 1 of which you can access for free at: http://n.neurology.org/content/100/2/88.full#ref-list-1
Subspecialty Collections	This article, along with others on similar topics, appears in the following collection(s): EMG http://n.neurology.org/cgi/collection/emg Peripheral neuropathy http://n.neurology.org/cgi/collection/peripheral_neuropathy Vasculitis http://n.neurology.org/cgi/collection/vasculitis Viral infections http://n.neurology.org/cgi/collection/viral_infections
Permissions & Licensing	Information about reproducing this article in parts (figures, tables) or in its entirety can be found online at: http://www.neurology.org/about/about_the_journal#permissions
Reprints	Information about ordering reprints can be found online: http://n.neurology.org/subscribers/advertise

Neurology® is the official journal of the American Academy of Neurology. Published continuously since 1951, it is now a weekly with 48 issues per year. Copyright © 2022 American Academy of Neurology. All rights reserved. Print ISSN: 0028-3878. Online ISSN: 1526-632X.

